

# **ENDOMETRIAL CANCER STRUCTURED REPORTING PROTOCOL**

## **(1<sup>st</sup> Edition 2011)**

### **Core Document versions:**

- AJCC Cancer Staging Manual 7<sup>th</sup> edition (including errata corrected with 5th reprint 10<sup>th</sup> Aug 2010).
- World Health Organization Classification of Tumours Pathology and Genetics of Tumours of the Breast and Female Genital Organs (2003).

ISBN: 978-1-74187-643-7

Publications number (SHPN): 110009

## Online copyright

© RCPA 2011

This work (**Protocol**) is copyright. You may download, display, print and reproduce the Protocol for your personal, non-commercial use or use within your organisation subject to the following terms and conditions:

1. The Protocol may not be copied, reproduced, communicated or displayed, in whole or in part, for profit or commercial gain.
2. Any copy, reproduction or communication must include this RCPA copyright notice in full.
3. With the exception of Chapter 6 - the checklist, no changes may be made to the wording of the Protocol including any Standards, Guidelines, commentary, tables or diagrams. Excerpts from the Protocol may be used in support of the checklist. References and acknowledgments must be maintained in any reproduction or copy in full or part of the Protocol.
4. In regard to Chapter 6 of the Protocol - the checklist:
  - The wording of the Standards may not be altered in any way and must be included as part of the checklist.
  - Guidelines are optional and those which are deemed not applicable may be removed.
  - Numbering of Standards and Guidelines must be retained in the checklist, but can be reduced in size, moved to the end of the checklist item or greyed out or other means to minimise the visual impact.
  - Additional items for local use may be added but must not be numbered as a Standard or Guideline, in order to avoid confusion with the RCPA checklist items.
  - Formatting changes in regard to font, spacing, tabulation and sequencing may be made.
  - Commentary from the Protocol may be added or hyperlinked to the relevant checklist item.

Apart from any use as permitted under the Copyright Act 1968 or as set out above, all other rights are reserved. Requests and inquiries concerning reproduction and rights should be addressed to RCPA, 207 Albion St, Surry Hills, NSW 2010, Australia.

First published: March 2011, 1st Edition (version 1.0)

## **Disclaimer**

The Royal College of Pathologists of Australasia ("College") has developed these protocols as an educational tool to assist pathologists in reporting of relevant information for specific cancers. While each protocol includes "standards" and "guidelines" which are indicators of 'minimum requirements' and 'recommendations', the protocols are a first edition and have not been through a full cycle of use, review and refinement. Therefore, in this edition, the inclusion of "standards" and "guidelines" in each document are provided as an indication of the opinion of the relevant expert authoring group, but should not be regarded as definitive or as widely accepted peer professional opinion. The use of these standards and guidelines is subject to the clinician's judgement in each individual case.

The College makes all reasonable efforts to ensure the quality and accuracy of the protocols and to update the protocols regularly. However subject to any warranties, terms or conditions which may be implied by law and which cannot be excluded, the protocols are provided on an "as is" basis. The College does not warrant or represent that the protocols are complete, accurate, error-free, or up to date. The protocols do not constitute medical or professional advice. Users should obtain appropriate medical or professional advice, or where appropriately qualified, exercise their own professional judgement relevant to their own particular circumstances. Users are responsible for evaluating the suitability, accuracy, currency, completeness and fitness for purpose of the protocols.

Except as set out in this paragraph, the College excludes: (i) all warranties, terms and conditions relating in any way to; and (ii) all liability (including for negligence) in respect of any loss or damage (including direct, special, indirect or consequential loss or damage, loss of revenue, loss of expectation, unavailability of systems, loss of data, personal injury or property damage) arising in any way from or in connection with; the protocols or any use thereof. Where any statute implies any term, condition or warranty in connection with the provision or use of the protocols, and that statute prohibits the exclusion of that term, condition or warranty, then such term, condition or warranty is not excluded. To the extent permitted by law, the College's liability under or for breach of any such term, condition or warranty is limited to the resupply or replacement of services or goods.

# Contents

Scope .....	5
Abbreviations .....	6
Definitions.....	7
Introduction.....	9
Authority and development .....	12
1 Clinical information and surgical handling .....	15
2 Specimen handling in the laboratory.....	19
3 Microscopic findings.....	24
4 Ancillary studies findings .....	29
5 Synthesis and overview .....	30
6 Structured checklist .....	32
7 Formatting of pathology reports .....	49
Appendix 1 Pathology request form for endometrial cancer .....	50
Appendix 2 Guidelines for formatting of a pathology report .....	53
Appendix 3 Example pathology report for endometrial cancer.....	54
Appendix 4 WHO histological classification (2003) <sup>7</sup> .....	57
Appendix 5 FIGO cancer staging system <sup>8</sup> .....	58
Appendix 6 2010 AJCC T Stage .....	59
Appendix 7 2010 AJCC N and M Stages.....	60
Appendix 8 Grading of endometrioid adenocarcinoma.....	62
Appendix 9 Nuclear grading of endometrioid adenocarcinoma .....	63
Appendix 10 Assessing microscopic depth of myometrial invasion.....	64
References .....	65

# Scope

Structured reporting aims to improve the completeness and usability of pathology reports for clinicians, improve decision support for cancer treatment and reduce the discordance in histology reporting of endometrial cancers<sup>1</sup>. The protocol provides the framework for the reporting of endometrial cancers arising above the internal cervical os (ie uterine corpus and isthmus), and can be used either as a minimum data set or a fully comprehensive report. With the adoption of surgical-pathological staging and a structured reporting format, a more individualized approach to therapy is possible.

This protocol contains standards and guidelines for the preparation of structured reports on hysterectomy specimens containing endometrial malignancies. In conjunction with a hysterectomy, the surgeon may decide to resect the left and right ovaries, the fallopian tubes, the omentum, the regional lymph nodes (pelvic/ para-aortic), obtain peritoneal biopsies and take pelvic washings for cytological examination. Excluded from consideration in this protocol are Pipelle endometrial samples, endometrial curettage specimens, carcinomas arising within adenomyosis and carcinomas arising in the cervical canal.

The handling of the resected tissues prior to receipt in the laboratory, the gross examination in the laboratory, the microscopic features, the pitfalls in interpretation and the construction of a structured histological report will be covered. Inadequate formalin fixation, ambiguous terminology and overestimation of the depth of myometrial invasion by carcinoma cells remain the commonest pitfalls in present practice.

The epithelial malignancies discussed include endometrioid adenocarcinoma and its variants, mucinous, serous, clear cell, mixed tumours, undifferentiated types and carcinosarcoma (malignant mixed Mullerian/mesodermal tumour) (refer to Appendix 4). Carcinosarcoma is now considered to represent a metaplastic carcinoma and not a sarcoma<sup>2</sup>. Rare types of endometrial malignancies such as neuroendocrine (both small cell and large cell), signet ring, transitional, squamous, lymphoepithelioma-like, and tumours metastatic to the endometrium will not be covered. Complex atypical endometrial hyperplasia and endometrial intraepithelial neoplasia are not discussed but serous intraepithelial carcinoma is included in view of our inability to define those features associated with its ability to metastasize. Leiomyosarcoma, endometrial stromal sarcoma, high grade (undifferentiated) stromal sarcoma, adenosarcoma, and carcinosarcoma are excluded.

Multiple or synchronous tumours (eg endometrioid carcinomas in the endometrium and ovary) should have separate protocols recorded for each tumour.

The reporting pathologist must have an appreciation of the treatment options available to the gynaecologist/oncologist in order to be a useful member of the multi disciplinary team. Optimal staging of endometrial carcinomas would allow recognition of patterns of tumour spread, permit reliable prognostication and assist in therapeutic decisions. In the 2010 AJCC TNM, separate staging systems for endometrial adenocarcinomas and uterine sarcomas were introduced. This approach is in accordance with changes adopted by the 2008 FIGO staging system. Appendices 6 and 7 include the definitions of TNM for uterine carcinomas and include the corresponding FIGO stage. Since peritoneal washings cytology is no longer part of either endometrial staging system, it will not be discussed in this protocol, although, if the result is available it should be included in the report.

Many controversies still exist in dealing with endometrial cancer and this protocol forms one part of an iterative development model which over time, no doubt, will undergo changes<sup>3</sup>.

# Abbreviations

AJCC	American Joint Committee on Cancer
FGT	Female genital tract
FIGO	Federation Internationale de Gynecologie et d'Obstetrique (International Federation of Obstetricians and Gynecologists)
IHC	Imunohistochemical tests on formalin fixed tissues
LVSI	Lymphovascular invasion by neoplastic cells
MELF	Endometrioid adenocarcinomas with an invasive pattern formed by microscopic, elongated and fragmented glands.
M/I	Mortality to incidence ratio
MSI	Microsatellite instability
PBS	Pharmaceutical Benefits Scheme
TNM	Tumour–node–metastasis (a staging system)
UICC	Union Internationale Contre le Cancer (International Union Against Cancer)
UK	United Kingdom
WHO	World Health Organization

# Definitions

The table below provides definitions for general or technical terms used in this protocol. Readers should take particular note of the definitions for 'standard', 'guideline' and 'commentary', because these form the basis of the protocol.

Ancillary study	An ancillary study is any pathology investigation that may form part of a cancer pathology report but is not part of routine histological assessment.
Clinical information	Patient information required to inform pathological assessment, usually provided with the specimen request form. Also referred to as 'pretest information'.
Commentary	<p>Commentary is text, diagrams or photographs that clarify the standards (see below) and guidelines (see below), provide examples and help with interpretation, where necessary (not every standard or guideline has commentary).</p> <p>Commentary is used to:</p> <ul style="list-style-type: none"><li>• define the way an item should be reported, to foster reproducibility</li><li>• explain why an item is included (eg how does the item assist with clinical management or prognosis of the specific cancer).</li><li>• cite published evidence in support of the standard or guideline</li><li>• clearly state any exceptions to a standard or guideline.</li></ul> <p>In this document, commentary is prefixed with 'CS' (for commentary on a standard) or 'CG' (for commentary on a guideline), numbered to be consistent with the relevant standard or guideline, and with sequential alphabetic lettering within each set of commentaries (eg CS1.01a, CG2.05b).</p>
General commentary	<p>General commentary is text that is not associated with a specific standard or guideline. It is used:</p> <ul style="list-style-type: none"><li>• to provide a brief introduction to a chapter, if necessary</li><li>• for items that are not standards or guidelines but are included in the protocol as items of potential importance, for which there is currently insufficient evidence to recommend their inclusion. (Note: in future reviews of protocols, such items may be reclassified as either standards or guidelines, in line with diagnostic and prognostic advances, following evidentiary review).</li></ul>

Guideline	<p>Guidelines are recommendations; they are not mandatory, as indicated by the use of the word 'should'. Guidelines cover items that are not essential for clinical management, staging or prognosis of a cancer, but are recommended.</p> <p>Guidelines include key observational and interpretative findings that are fundamental to the diagnosis and conclusion. Such findings are essential from a clinical governance perspective, because they provide a clear, evidentiary decision-making trail.</p> <p>Guidelines are not used for research items.</p> <p>In this document, guidelines are prefixed with 'G' and numbered consecutively within each chapter (eg G1.10).</p>
Macroscopic findings	Measurements, or assessment of a biopsy specimen made by the unaided eye.
Microscopic findings	In this document, the term 'microscopic findings' refers to histological or morphological assessment.
Predictive factor	A <i>predictive factor</i> is a measurement that is associated with response or lack of response to a particular therapy.
Prognostic factor	A <i>prognostic factor</i> is a measurement that is associated with clinical outcome in the absence of therapy or with the application of a standard therapy. It can be thought of as a measure of the natural history of the disease.
Standard	<p>Standards are mandatory, as indicated by the use of the term 'must'. Their use is reserved for core items essential for the clinical management, staging or prognosis of the cancer.</p> <p>The summation of all standards represents the minimum dataset for the cancer.</p> <p>In this document, standards are prefixed with 'S' and numbered consecutively within each chapter (eg <b>S1.02</b>).</p>
Structured report	A report format which utilizes standard headings, definitions and nomenclature with required information.
Synoptic report	A structured report in condensed form (as a synopsis or precis).
Synthesis	Synthesis is the process in which two or more pre-existing elements are combined, resulting in the formation of something new. In the context of structured pathology reporting, synthesis represents the integration and interpretation of information from two or more chapters to derive new information.

# Introduction

## Endometrial cancers

Endometrial cancer is the commonest female genital tract malignancy occurring in the Western World. The incidence is known to be increasing with 1,700 new cases and approximately 230 deaths per year in Australia<sup>4-6</sup>. The tumours affect a wide age range, but most tumours arise in postmenopausal women with 88% of affected women 50 years of age or older<sup>7</sup>. The peak age incidence is in the 60-64 year age group. The overall mortality to incidence ratio (M/I) is 18% which is approximately half the M/I for cervical cancer and one quarter of that for ovarian cancers.

Most endometrial malignancies (80-85%) are related to sustained unopposed oestrogen, either endogenous or exogenous in origin, and are an example of the hyperplasia-carcinoma sequence. Endogenous hyperoestrogenism may be due to obesity, anovulatory cycles, polycystic ovarian disease, infertility, late menopause or other causes. The prototypical tumour in this group, so-called Type 1, is endometrioid adenocarcinoma. These tumours are usually low grade, co-exist with atypical endometrial hyperplasia, are confined to the uterus at the time of diagnosis (70%) and have a relatively good prognosis<sup>8</sup>.

The non-endometrioid endometrial malignancies, or so-called Type 2, affect older women, are oestrogen independent, arise in an atrophic endometrium, have - in >50% of women - extra-uterine spread at the time of presentation, and a poor prognosis. In contrast to endometrioid carcinoma, the existence of a precursor lesion in Type 2 tumours is controversial and the tumours are, by definition, considered to be *ab initio* high grade. Type 2 tumours include both serous and clear cell carcinomas. The term 'minimal carcinoma' is applied to both *in situ* and superficially invasive serous carcinoma, as metastases have been found despite minimal if any stromal invasion<sup>9-10</sup>.

In contrast to grade 3 (FIGO) endometrioid carcinomas, undifferentiated endometrial carcinomas commonly present with advanced stage (54% versus 30%) and the mortality is twice that of Grade 3 endometrioid carcinomas<sup>11</sup>.

## Importance of histopathological reporting

Endometrioid adenocarcinoma has a well defined natural history closely related to surgical-pathological staging. The depth of myometrial invasion, the involvement of vessels, cervical stroma, lymph nodes and parametrium are closely related to prognosis. Many of the early stage, well differentiated endometrioid tumours show a good response to progestagen hormone therapy. Vaginal vault recurrence in women with endometrioid adenocarcinoma often responds well to surgery and / or radiotherapy.

In contrast endometrial serous carcinoma, clear cell carcinoma and carcinosarcomas are known to undergo early dissemination by both lymphatics and/or retrograde transtubal spread<sup>12-15</sup>. On initial presentation the incidence of extra-uterine disease, particularly omental and peritoneal involvement, is far higher than that with endometrioid carcinoma. The 5-year survival rate is poor and decreases progressively in the order clear cell carcinoma, serous carcinoma, carcinosarcoma.

## Benefits of structured reporting

Structured pathology reports with standardised definitions for each component have been shown to significantly enhance the completeness and quality of data provided to

clinicians, and have been recommended both in North America and the United Kingdom<sup>16-19</sup>.

The College of American Pathologists and the Royal College of Pathologists (UK) have recently published useful protocols for the reporting of cancer<sup>20-21</sup>. A protocol for the management of endometrial cancer and endorsed by the Royal College of Pathologists of Australasia and other Australasian organisations is long overdue.

There are a number of treatment trials for endometrial cancers being conducted at the moment. However to facilitate patient enrolment, the collection of necessary information (key elements) as to histopathological type, baseline staging, etc, is mandatory. Use of a structured reporting format facilitates consistent and comprehensive reports, allows easy extraction of the necessary information and ensures that no critical data are omitted.

## Design of this protocol

This structured reporting protocol provides a complete framework for the assessment and documentation of all the pathological features of endometrial cancers.

Mandatory elements (standards) are differentiated from those that are not mandatory but are recommended (guidelines). It is anticipated that some of the pathological features included under guidelines will become standards in the future as our knowledge base increases. Consistency and speed of reporting is improved by the use of discrete data elements recorded from the checklist. However, the pathologist is encouraged to include free text or narrative to document any other relevant issues, to give reasons for coming to a particular opinion, to explain any points of uncertainty and to avoid any ambiguity.

The structure provided by the following chapters, headings and subheadings describes the elements of information and their groupings, but does not necessarily represent the format of either a pathology report (Chapter 7) or checklist (Chapter 6). These, and the structured pathology request form (Appendix 1) are templates that represent information from this protocol, organised and formatted differently to suit different purposes.

## Key documents

- *Guidelines for Authors of Structured Cancer Pathology Reporting Protocol*, Royal College of Pathologists of Australasia, 2009<sup>22</sup>
- *The Pathology Request-Test-Report Cycle — Guidelines for Requesters and Pathology Providers*, Royal College of Pathologists of Australasia, 2004<sup>23</sup>
- *AJCC Cancer Staging Manual* 7<sup>th</sup> edition, American Joint Committee on Cancer 2010<sup>6</sup>
- *TNM Classification of Malignant Tumours*, 7<sup>th</sup> edition International Union against Cancer (UICC). eds Sobin L, Gospodarowicz M, Wittekind C. 2009. Wiley-Blackwell, Chichester, UK and Hoboken, New Jersey<sup>24</sup>
- *Tumours of the Breast and Female Genital Organs. Pathology and Genetics*, World Health Organization Classification of Tumours, eds Tavassoli FA, Devilee P. 2003. IARC Press, Lyon, France<sup>5</sup>
- *Gynecologic Oncology*, 5<sup>th</sup> edition. Berek JS, Hacker NE. Walters Kluwer health/Lippincott Williams & Wilkins. 2010<sup>8</sup>
- Wittekind C, Henson D, Hutter R and Sobin L (eds) (2001). *TNM Supplement: A Commentary on Uniform Use*, Wiley-Liss, New York<sup>25</sup>

## **Updates since last edition**

Not applicable

# Authority and development

This section provides details of the committee involved in developing this protocol and the process by which it was developed.

## Protocol developers

This protocol was developed by an expert committee, with assistance from relevant stakeholders.

## Expert group

### Protocol development committee for Endometrial Cancer

Dr Nick Mulvany, pathologist (Lead Author)  
Associate Professor David Allen, gynaecologist oncologist  
Associate Professor Kailash Narayan, radiation oncologist  
Dr Colin Stewart, pathologist

### General expert committee for all gynaecological cancers

Dr Nick Mulvany, pathologist (Chair)  
Associate Professor David Allen, gynaecologist oncologist  
Associate Professor Kailash Narayan, radiation oncologist  
Dr Colin Stewart, pathologist  
Professor Neville Hacker, gynaecologist oncologist  
Professor Peter Russell, pathologist  
Dr Jim Scurry, pathologist  
Associate Professor Peter Grant, gynaecologist oncologist  
Dr Marsali Newman, pathologist  
Dr Kerry Ireland-Jenkin, pathologist  
Dr Linda Mileshkin, medical oncologist  
Associate Professor David Ellis, pathologist (RCPA representative)

## International Liaison

Dr. Christopher Otis, Chair of the Gynecologic Tumors Cancer Committee, College of American Pathologists

## Acknowledgements

The gynaecological cancer expert committee wishes to thank all the pathologists and clinicians who contributed to the discussion around this document.

## Stakeholders

ACT Health

Anatomical Pathology Advisory Committee (APAC)

Australian Association of Pathology Practices Inc (AAPP)

Australian Cancer Network

Australian Commission on Safety and Quality in Health Care

Australian Society of Clinical Oncologists (ASCO)

Australian Society of Colposcopy and Cervical pathology (ASCCP)

Australian Society of Cytology (ASC)

Australian Society of Gynaecologic Oncologists (ASGO)

Cancer Australia

Cancer Council ACT

Cancer Council NSW

Cancer Council Queensland

Cancer Council SA

Cancer Council Tasmania

Cancer Council Victoria

Cancer Council Western Australia

Cancer Institute NSW

Cancer Services Advisory Committee (CanSAC)

Cancer Voices

Clinical Oncology Society of Australia (COSA)

Department of Health and Ageing

Grampians Integrated Cancer Services (GICS)

Health Informatics Society of Australia (HISA)

International Federation of Obstetricians and Gynecologists (FIGO)

International Gynecological Cancer Society (IGCS)

Medical Software Industry Association (MSIA)

National Breast and Ovarian Cancer Centre (NBOCC)

National Coalition of Public Pathology (NCOPP)

National E-Health Transition Authority (NEHTA)

National Pathology Accreditation Advisory Council (NPAAC)

National Round Table Working Party for Structured Pathology Reporting of Cancer.

New Zealand Guidelines Group (NZGG)

NSW Department of Health

Peter MacCallum Cancer Institute

Queensland Cooperative Oncology Group (QCOG)

Representatives from laboratories specialising in anatomical pathology across Australia

Royal Australasian College of Physicians (RACP)  
Southern Cancer Network, Christchurch, New Zealand  
Southern Melbourne Integrated Cancer Service (SMICS)  
Standards Australia  
The Medical Oncology Group of Australia  
The Royal Australasian College of Surgeons (RACS)  
The Royal Australian and New Zealand College of Obstetricians & Gynaecologists (RANZCOG)  
The Royal Australian and New Zealand College of Radiologists (RANZCR)  
The Royal Australian College of General Practitioners (RACGP)  
The Royal College of Pathologists of Australasia (RCPA)  
6Victorian Cooperative Oncology Group (VCOG)  
Western Australia Clinical Oncology Group (WACOG)

## **Secretariat**

Meagan Judge, Royal College of Pathologists of Australasia.

## **Development process**

This protocol has been developed following the seven-step process set out in *Guidelines for Authors of Structured Cancer Pathology Reporting Protocols*<sup>22</sup>.

Where no reference is provided, the authority is the consensus of the expert group.

# 1 Clinical information and surgical handling

This chapter relates to information that should be collected before the pathology test, and procedures that are required before handover of specimens to the laboratory.

The standards and guidelines below specify the particular information and specimens required for endometrial cancers. Some of this information can be collected on generic pathology request forms; any additional information required specifically for the reporting of endometrial cancers may be recorded on a separate data sheet.

Appendix 1 provides a standardised data sheet that may be useful in obtaining all relevant information.

## Specimen Request

### **S1.01 Adequate demographic and request information must be provided with the specimen by the requesting clinician.**

CS1.01a The Royal College of Pathologists of Australasia (RCPA) *The Pathology Request-Test-Report Cycle — Guidelines for Requesters and Pathology Providers* must be adhered to<sup>23</sup>. The RCPA guidelines specify the minimum information to be provided by the requesting clinician for any pathology test.

Items relevant to cancer reporting protocols include:

- patient name
- date of birth
- sex
- identification and contact details of requesting doctor
- date of request

Additional information specified in the RCPA *The Pathology Request-Test-Report Cycle — Guidelines for Requesters and Pathology Providers* such as the specimen type and clinical information relevant to the investigation is catered for in the following standards and guidelines.

CS1.01b The patient's ethnicity must be recorded, if known.

G1.01 The patient's health identifiers should be recorded where provided.

CG1.01a The patient's health identifiers may include the patient's Medical Record Number as well as a national health number such as a NHI or the Individual Healthcare Identifier (IHI).

### **S1.02 The pathology accession number of the specimen must be recorded upon receipt in the laboratory.**

### **S1.03 The principal clinician involved in the patient's care and responsible for investigating the patient must be identified.**

### **S1.04 The operative procedure and/or specimen type must be recorded.**

- CS1.04a The nature of the operative procedure refers to the surgical technique employed ie total, subtotal or radical hysterectomy, with/without other structures eg ovaries, etc. The specimen type refers to the whole or part of an anatomical organ resected.
- CS1.04b Site is an important identifier especially when multiple biopsies are performed. A diagram or photograph can facilitate.
- Site is particularly relevant for lymph nodes whether pelvic or para-aortic, left or right side. The paired pelvic lymph nodes include the obturator, parametrial, presacral, internal, external and common iliac lymph nodes. Usually the parametrial nodes are only found if a radical hysterectomy has been performed.
- In particular, it is useful to specify the level of nodal involvement in relation to the aortic bifurcation, origin of the inferior mesenteric artery, renal vessels, etc, in case of any subsequent radiotherapy.
- G1.03 Any discrepancy noted between the contents of the specimen container and the information stated on the specimen request form and also on the specimen label should be promptly resolved usually by contacting the operating surgeon<sup>26</sup>.
- G1.04 The clinical working diagnosis or differential diagnosis should be recorded.
- CG1.04a Providing the provisional clinical diagnosis or differential diagnosis improves clinicopathological correlation and diagnostic accuracy.
- In addition any unexpected or unexplained finding can be rapidly communicated to the surgeon via telephone. With this approach pre-analytical errors may be resolved before some inappropriate action has been taken<sup>26</sup>.
- G1.05 Details of previous biopsy or cytology results should be recorded.
- CG1.05a Previous biopsy or cytology results may include Pipelle endometrial sample, endometrial curettage, peritoneal washings, or Pap smears. In addition to the results, the details of the laboratory that reported the specimens should be provided in order to allow prompt review of any relevant material.
- All of this information may influence the particular method chosen by the pathologist for sectioning and sampling the resected surgical specimens<sup>27-28</sup>. Other possible benefits of adequate information include the opportunity for ancillary studies.
- G1.06 The details of any previous or current treatment of the present tumour should be recorded.
- CG1.06a After chemo- and radiotherapy extensive sampling of the specimen may be necessary to identify any residual tumour cells. Viable tumour may persist as microscopic sanctuary-groups scattered deep within sclerotic fibrous tissue. Furthermore both the classical architectural and/or cytomorphological features of the tumour may be altered by prior hormone therapy, chemo- or radiotherapy<sup>29-31</sup>.

G1.07 Relevant details of any additional prior cancer diagnosis should be recorded.

CG1.07a Information regarding prior malignancies should be recorded. If necessary, review of the previous specimens may assist in resolving the origin of the current tumour.

G1.08 Relevant details of any relevant family history should be recorded.

CG1.08a The information regarding prior malignancies coupled with the family histories may assist in the identification of a propositus for inherited cancer-susceptibility<sup>32</sup>. Endometrial cancer in women under the age of 50 has a 9% incidence of mutation in DNA mismatch repair genes (Lynch syndrome or Hereditary Non-polyposis Colorectal Cancer/HNPCC). If coupled with one of the HNPCC-related cancers in a first degree relative, then the incidence is increased to 43%<sup>33-34</sup>. These endometrial carcinomas and some sporadic microsatellite instability (MSI) positive tumours may have distinctive clinico-pathological features although this point is hotly debated in the literature<sup>35-36</sup>.

**S1.05 Metastatic disease must be recorded.**

CS1.05a The operating surgeon must record on the laboratory request form any information, either from pre-operative investigations or intra-operative visual inspection, as to the presence of metastatic disease. For accuracy and completeness the data may have to be entered at the conclusion of the surgical procedure.

**S1.06 Post-operative residual tumour must be recorded.**

CS1.06a The operating surgeon must record on the laboratory request form any information as to the presence of residual malignant disease. The residual tumour may be minimal in amount or form a large bulky mass. For accuracy and completeness the data may have to be entered at the conclusion of the surgical procedure.

## **Specimen handling by the surgeon**

G1.09 The surgeon may wish to draw the attention of the pathologist to a particular area which he would like examined by attaching a suture.

CG1.09a If the surgeon has an area of specific interest on the resected specimen this can be marked by a suture. An explanation of the significance of the suture can be added to the specimen request form. However, if the question is complicated, direct discussion with the reporting pathologist may be necessary.

**S1.07 If frozen section examination is required, then the uterus must be sent to the laboratory in a fresh state and without any added formalin.**

- G1.10 The pathologist or laboratory must be phoned and informed about the request for the frozen section, the arrangements to courier the specimen to the laboratory, the time of dispatch of the specimen from the operating theatre and the specific purpose or indication for the frozen section (e.g. depth of myoinvasion).
- G1.11 Specimens received out of normal working hours.
- CG1.11a The laboratory should be forewarned if a surgical specimen is likely to arrive outside of normal working hours, particularly if sent fresh. If sent in formalin, the uterus has to be opened and enough formalin present to ensure adequate fixation (for method refer CS2.01a & b). If there is any delay in the specimen reaching the laboratory the surgeon may decide, upon his own discretion, to open the uterus in the coronal or sagittal plane into two equal halves in order to ensure adequate fixation by formalin. Prior discussion with the reporting pathologist is however recommended to ensure that gross examination and histological assessment are not compromised.
- CG1.11b Laboratories should have a written protocol in place for checking that specimens received out of normal working hours are promptly opened and adequately fixed in formalin.

## 2 Specimen handling in the laboratory

This chapter relates to the procedures required after the information has been handed over from the requesting clinician and the specimen has been received in the laboratory.

### Specimen handling in the laboratory

#### G2.01 Tissue banking.

The pathologists may be asked to provide tissue samples from endometrial cancers for tissue banking or other research purposes. The decision to provide tissue should only be made in cases in which the diagnostic process and pathological evaluation will not be compromised. As a safeguard, use of that tissue sample may be put on hold until the diagnostic process is complete so that it can, if necessary, be retrieved.

#### G2.02 Gross photography of the resected uterus allows subsequent checking of the recorded findings. It can also be of assistance to the surgeon especially if the case is subsequently discussed and any points require clarification or substantiation.

### S2.01 Adequate fixation is required to ensure high quality pathological assessment.

CS2.01a Upon receipt of the specimen, the uterus must be promptly opened out into two equal halves to ensure adequate fixation. The separate halves are immersed in formalin with the endometrial surfaces exposed in order to ensure adequate fixation. Pinning out of the specimen reduces the amount of tissue distortion.

#### G2.03 The volume of formalin must be at least 5 times the estimated volume of the resected surgical specimen. Fixation overnight or for 24 hours is required. Prolonged fixation may impair some immunohistochemical tests<sup>37</sup>.

#### G2.04 In order to avoid artefacts and laboratory contamination by malignant cell floaters, the resected organs and tissue uninvolved by carcinoma should be sectioned first during the cut-up procedure.

CG2.04a Before sectioning the uterus, all tissues which are not obviously involved by tumour on gross examination such as lymph nodes, omentum, peritoneal biopsies, ovaries, fallopian tubes, and parametrium are sectioned. This approach reduces the possibility of contamination by malignant cells. Necrotic, papillary and autolytic endometrial tumours are often responsible for contamination of uninvolved tissue by 'malignant cell floaters'.

### S2.02 The surgical margins and any abnormal serosal surfaces of the uterus must be marked with ink in order to assess areas suspicious for tumour involvement.

CS2.02a Inking may be relevant if there is any visible abnormality involving the uterine serosa or if tumour is seen involving the cervical or vaginal surgical margin. Abnormalities of the uterine serosa may reflect trans-myometrial tumour penetration or the attachment site of peritoneal adhesions for some unrelated cause.

Identification of the inked surface on microscopic examination provides confirmation of tumour involvement. The use of different coloured inks will assist in discriminating between the various specified abnormal areas. The colour red should be avoided since the colour contrast in H&E stained tissues is poor.

## Macroscopic findings

**S2.03 All measurements are in SI units.**

**S2.04 The resected lymph nodes must be examined and findings recorded.**

CS2.04a The nodes must be dissected out from the fat and the number of nodes from each nominated anatomical site recorded. The maximum diameter of each lymph node must be measured and if multiple nodes found then a size-range must be recorded. Any individual nodes larger than 5mm can be subdivided, and, if necessary, placed within several cassettes and the fact recorded in the macroscopic description. All recognizable nodal tissue must be blocked and all of the remaining fat must be separately blocked in order to find any impalpable microscopic lymph nodes.

The total number of lymph nodes in each group must be counted as this gives some indication to specimen adequacy. Subsequent microscopic examination may lead to amendment to the total number of nodes counted on gross examination.

CS2.04b Palpation is often more sensitive than serial sectioning for the detection of small nodes.

**S2.05 The omental tissue must be examined and the findings recorded.**

CS2.05a The gross appearance and measurements of the omental tissue are recorded and the specimen serially sliced. If tumour involvement is minimal, palpation may be more sensitive than serial sectioning. A crude estimate of the proportion of fat replaced by tumour must also be recorded since it gives some idea as to gross tumour-volume. Any abnormal or suspicious areas are sampled.

**S2.06 The peritoneal biopsies must be examined and findings recorded.**

CS2.06a The peritoneal biopsies from each nominated anatomical site must be described, measured, and blocked *in toto*. Any gross abnormalities must be recorded and the tissue blocked *in toto*.

**S2.07 The resected ovaries must be examined and findings recorded.**

CS2.07a The gross appearances and measurements of each ovary are recorded. Any nodules or roughening of the ovarian surface are recorded and sampled.

CS2.07b If on clinical or pathological grounds there is any knowledge or suspicion of a hereditary cancer syndrome, then all of the ovarian tissue must be processed.

**S2.08 The resected fallopian tubes must be examined and findings recorded.**

CS2.08a The gross appearances and measurements of each fallopian tube are recorded. Any dilatation of a fallopian tube must be noted. Previous tubal interruption (eg.ligation), either recent or old, must be recorded since it reduces the possibility of retrograde transtubal tumour spread. Any suspicious areas are sampled.

CS2.08b If on clinical or pathological grounds there is any knowledge or suspicion of a hereditary cancer syndrome, then all of the tubal tissue must be processed.

**S2.09 The external appearance of the uterus as received in the laboratory must be recorded.**

CS2.09a Record whether the uterus was received intact or opened. The uterus is orientated by the comparative heights of the anterior and posterior peritoneal reflections, the attached adnexae or preferably both. Orientation of the uterus allows identification of the left and right sided fallopian tube and ovary. If the specimen cannot be oriented contact the surgeon or call one serosal aspect of the uterus 'A' and the other 'B'.

The peritoneal surfaces are examined with particular attention paid to the vaginal peritoneal reflection of the Pouch of Douglas in order to exclude any possible metastatic tumour deposits.

**S2.10 The weight of the uterus (without ovaries and tubes) must be recorded.**

**S2.11 Various measurements of the uterus must be recorded in a reproducible and accurate manner.**

CS2.11a Referral to the specimen request form will give some idea as to the optimal method to examine the uterus. The basic aspects of the macroscopic assessment of a hysterectomy specimen are described in standard texts<sup>27-28,38</sup>.

A full description of the uterus with measurements in three dimensions includes: midline fundal-serosa to ectocervix, maximum intercornual distance and maximum anterior to posterior dimension.

**S2.12 The precise location and dimensions of the endometrial tumour must be recorded.**

CS2.12a The precise location and dimensions in all three planes of all visible abnormalities (especially thickening of the endometrium or polyps) must be recorded. The use of the word 'edge' referring to the periphery of a lesion and 'margin' referring to the surgical specimen margins will avoid potential misunderstanding. A diagram or photograph can provide a permanent record for

subsequent verification.

G2.05 The closest distance of the endometrial tumour from the inferior surgical resection margin of the specimen should be recorded.

**S2.13 When sectioning the uterus, tissue blocks must be obtained in a methodical fashion and the block identification key recorded.**

CS2.13a All cassettes are identified, using a block identification key, as to the area of the sampled uterine tissue. Unless a diagrammatic representation forms part of the completed and permanent report, it should not be used as a substitute for a typed-up 'block identification key'.

CS2.13b The selection of the specific tissue blocks is dictated by the lesion identified on gross examination and performed in a systematic manner to ensure that a microscopic estimate of tumour size is possible. Processing of the abnormal area, including the full thickness of the underlying myometrium in consecutive sections taken perpendicular to the serosal surface will provide a reliable measurement of the maximum tumour invasive depth. Composite tissue blocks may be necessary depending upon the thickness of the myometrium. The individual cassettes must be sequentially labelled and individually identified as to source in case additional tissue sampling may be subsequently required.

As a minimum the following sections must be obtained:

- representative sections of the tumour itself including the deepest focus of myometrial invasion,
- transverse section through the isthmus ("lower uterine segment") immediately proximal to the endocervix,
- a longitudinal section through the isthmus ("lower uterine segment")
- sections through both cornua,
- single midline sections through the anterior and posterior cervical lips
- in the case of large endometrial tumours, contiguous sections to include the most inferior part of the tumour and the external anatomical os. This will allow microscopic confirmation of any cervical stromal involvement
- normal or uninvolved endometrium
- left and right parametrium.

**S2.14 The myometrial invasive depth as assessed on gross examination and the thickness of the adjacent normal myometrial wall must be recorded.**

CS2.14a Close serial slicing of any lesion and the underlying myometrium will aid in the gross identification of the deepest tumour infiltration point. Any myo-invasive tumour may have an off-white/yellow appearance, the normal myometrial texture may be effaced, or a 'tide-mark' representing the tumour interface with normal myometrium may be evident. The apparent depth of myoinvasion (excluding any exophytic tumour component) and the thickness of the adjacent normal myometrial wall must be recorded<sup>39</sup>. These measurements can be subsequently compared with those reported on microscopic examination. The estimated invasive depth on gross examination is surprisingly accurate in grade 1 carcinomas and in tumours of less than 20mm diameter<sup>40</sup>.

If no endometrial abnormality is visible on gross examination, the tumour may have been originally polypoid in configuration and totally removed by a previous curettage. In such cases the endomyometrium is serially sliced in the longitudinal plane in order to check for an endophytic tumour component. If after this exercise, no areas suspicious for myoinvasion are discovered, then all of the endometrial tissue must be blocked. Each cornual recess must also be checked for any occult tumour.

**S2.15 The surface of the cervical canal and the underlying stroma is examined for tumour involvement and the findings recorded.**

CS2.15a Any apparent extension of invasive tumour or isolated foci of apparent tumour involving the cervix must be recorded. The tumour dimensions and the shortest distances from the inferior surgical margin and the external anatomical os must be recorded. In addition the maximum tumour invasive depth and the normal thickness of the cervical wall must be recorded.

If on gross examination the tumour appears to be of cervical rather than endometrial origin, then the protocol for primary cervical cancers must be consulted<sup>41</sup>. This protocol will be promulgated in the near future.

G2.06 Any additional relevant macroscopic comments should be recorded.

### 3 Microscopic findings

Microscopic findings relate purely to histological assessment. Information derived from multiple investigational modalities, or from two or more chapters are described in Chapter 5.

#### **S3.01 Involvement of the lymph nodes must be recorded.**

- CS3.01a The number of nodes in each anatomical group involved by metastatic carcinoma as well as those free of tumour must be recorded in an unambiguous fashion. These figures are usually expressed as an absolute ratio of involved nodes/ total nodes resected.
- CS3.01b The maximum dimension of the metastatic deposit or in the case of multiple deposits a size-range must be recorded. The presence or absence of extranodal tumour spread must be recorded.
- CS3.01c Metastases involving the inguinal lymph nodes or intra-abdominal nodes other than the pelvic or para-aortic are considered distant metastases<sup>42</sup> (refer to Appendix 7). The para-aortic nodes are rarely involved without gross involvement of the pelvic nodes<sup>8</sup>. Of the retroperitoneal lymph nodes, the intercavo-aortic and pre-paraaortic are most commonly involved<sup>43</sup>.

#### **S3.02 Involvement of the omentum must be recorded.**

- CS3.02a The omental fat may be extensively replaced by metastatic carcinoma or the involvement may be unexpected from gross examination.

#### **S3.03 Involvement of the peritoneum must be recorded.**

- CS3.03a Peritoneal keratin granulomas may be related to an endometrioid carcinoma with squamous differentiation. In isolation, the prognosis is unaffected by the presence of such lesions.

#### **S3.04 Involvement of the ovaries must be recorded.**

- CS3.04a The presence of similar appearing tumours in the endometrium and ovary but with no other evidence of spread occurs quite commonly and appears to represent synchronous carcinomas. As expected the prognosis is better than with metastatic involvement.

With metastatic carcinomas the ovaries may be extensively replaced or the involvement may be unexpected from gross examination. The involvement of the peritoneal aspect generally reflects transcoelomic tumour spread while involvement of the hilar vessels is often due to retrograde lymphatic spread.

#### **S3.05 Involvement of the fallopian tubes must be recorded.**

- CS3.05a The fallopian tube may be directly involved by endometrial adenocarcinoma cells in continuity, by free floating carcinoma cells lying within the lumens, involvement of the vessels in the tubal walls, or by intraepithelial carcinoma<sup>44-46</sup>.

Many cases of multicentric endometrioid adenocarcinomas have been proven by genetic studies to represent synchronous primary carcinomas. In contrast some serous carcinomas with multiple sites of tubal involvement represent tumour transplantation from a single source<sup>44-45</sup>. With any multifocal serous carcinoma the original site of tumour origin is problematic and the degree of uncertainty should be reflected in the pathology report.

The presence of intraluminal carcinoma cells may be related to pre-operative hysteroscopy or spontaneous single cell shedding by the tumour. Correlation with the peritoneal washings is recommended for the sake of completeness<sup>46</sup>.

G3.01 If intraepithelial carcinoma of serous type is determined, then the entire length of both fallopian tubes, including the fimbriae, should be blocked and histologically examined<sup>44</sup>.

CG3.01a Some cases of serous tubal intraepithelial carcinoma involving the lateral fallopian tubes may be associated with ovarian and peritoneal carcinomas of both BRCA-related and sporadic types<sup>47-48</sup>.

**S3.06 The histological type of the endometrial adenocarcinoma must be recorded. If multiple histological types are identified then the approximate relative percentages of each type must be stated.**

CS3.06a Endometrioid adenocarcinomas are formed by neoplastic glands with a glandular, tubular, cribriform or papillary growth pattern and may show a variety of histological patterns<sup>49</sup>.

Mucinous endometrial adenocarcinoma has the same growth pattern as endometrioid carcinoma but 50% or more cells must contain intracytoplasmic mucin. Focal mucinous differentiation is extremely common in otherwise unremarkable endometrioid adenocarcinomas. Some authorities believe that such tumours should be classified as endometrioid adenocarcinomas with mucinous change, mixed endometrioid/mucinous carcinomas and pure mucinous tumours using the general rule of <10% for the first group, 10-50% for the second and >50% for the third.

Serous and clear cell carcinomas behave as high grade carcinomas and have been comprehensively summarized in a recent publication<sup>49</sup>. The tumours may occur together and, if so, the percentage contribution of each must be recorded.

Mixed carcinomas, in some classifications, require a combination of a Type 1 and a Type 2 endometrial carcinoma with the smaller component occupying at least 10% of the tumour mass<sup>5</sup>. The literature on the minimal proportion of a high grade carcinoma required to affect prognosis is limited. It is advisable to record the relative proportions of each tumour type irrespective of the percentage tumour contribution and even when the identified tumour types belong exclusively to Type 1 or Type 2.

Carcinosarcomas are high grade biphasic malignant tumour tumours with a mixed carcinomatous and sarcomatous phenotype but are considered to represent metaplastic carcinomas<sup>50</sup>. Note that the epithelial differentiation in such tumours may also be "mixed", and of

either Type 1 or Type 2.

Undifferentiated carcinomas constitute between 1 and 9 % of all endometrial carcinomas<sup>11</sup>. The WHO defines undifferentiated carcinoma as a tumour with complete absence of glands or papillae and formed by patternless sheets of medium sized, monotonous, round or polygonal cells with significant nuclear atypia, dense chromatin and numerous mitotic figures.

**S3.07 The histologic grade of the endometrial tumour must be recorded and the specific grading system used.**

CS3.07a The FIGO grading system applies only to endometrioid carcinomas (including mucinous types). Endometrioid adenocarcinoma is graded on the proportion of the glandular (ie. non-squamous non-morular) solid growth of the carcinoma (refer Appendix 8). The grading system also recognizes the independent prognostic value of notable nuclear atypia in the glandular cell component which is inappropriate for the architectural pattern<sup>51-52</sup> (refer to Appendix 9). Although the percentage of cells with notable nuclear atypia has not been specified, many authorities require a majority of cells to be affected. The grading is irrespective of the grade of any co-existing squamous component<sup>53</sup>. Grade 3 endometrioid carcinoma is formed by a single cytomorphological cell type showing only focal glandular differentiation or solid areas containing well demarcated trabeculae, cords or cell-groups.

G1 = 5% or less of a nonsquamous or nonmorular solid growth pattern

G2 = 6-50% of a nonsquamous or nonmorular solid growth pattern

G3 = More than 50% of a nonsquamous or nonmorular solid growth pattern

\* Notable nuclear atypia, which exceeds that which is routinely expected for the architectural grade, increases the tumor grade by 1<sup>6</sup>.

Serous carcinoma, clear cell carcinoma, and carcinosarcoma are considered high grade or, less correctly, grade 3 tumours (AJCC).

For a number of reasons the tumour grade based on representative sampling from the formalin-fixed hysterectomy specimen is more reliable than that based on the pre-operative Pipelle sample, endometrial curettage, or frozen section examination<sup>54</sup>.

G3.02 The year of publication of the grading system should be recorded.

CG3.02a Since there are often substantial differences between consecutive published versions of a grading system, the year of publication must be documented either in the laboratory cut-up manual or in the printed report.

**S3.08 The maximal microscopic depth of myometrial invasion by neoplastic cells must be recorded. This is quoted in mm invasive depth out of total**

**(i.e. normal uninvolved) myometrial thickness.**

CS3.08a In endometrioid adenocarcinomas the prognosis and the incidence of nodal metastases are related to myometrial invasive depth and histologic grade<sup>55-56</sup>. This fractional myometrial invasion by tumour cells i.e. ratio of myometrial invasive depth to total normal myometrial thickness, is predictive of lymph node metastases in high risk endometrial cancers<sup>57</sup>. However measurement of invasive depth must be reproducible in spite of any surface ulceration, tumour-necrosis, polypoid tumours, intramyometrial leiomyomas, adenomyosis, or pre-operative curettage.

The depth of myometrial invasion is measured from the normal endometrium-myometrium interface (not the surface of the intracavitary or exophytic tumour) to the deepest tumour infiltrative focus and is most reliably recorded using a calibrated ocular micrometer (refer Appendix 10). Since the endometrium-myometrium interface is normally undulating a representative measurement is obtained from one or more histological slides<sup>39</sup>. Some pathologists find the measurement from the uterine serosa to the nearest (i.e. deepest) tumour infiltration point to be more reproducible and subtract this from the normal myometrial wall thickness to get the tumour invasive depth. Some pathologists believe that tumour infiltrating deeply into or through the myometrial arcuate vascular plexus proves infiltration into the outer half of the uterus. However myoinvasion short of the plexus does not equate with infiltration confined to the inner half of the myometrium<sup>58</sup>.

The measurements of invasive depth and normal myometrial thickness obtained on microscopic examination can be compared with those recorded on gross examination. Any discrepancies between the two sets of measurements need to be resolved. Overestimation of myometrial invasive depth is common if the chosen tissue section was obtained from the cornual region where the myometrium is naturally thinned. Over-estimation of tumour invasive depth may also occur with exophytic tumours (see above), composite tissue block not available, use of imprecise terminology (e.g. tumour thickness), adenomyosis showing hyperplasia, adenomyosis with an attenuated layer of stromal cells, misinterpretation of endometrial-myometrial interface irregularity as invasion, artefactual traumatic tumour displacement, vascular involvement, examining tissue sections from the cornual myometrium, etc. Under-estimation occurs with incorrect paraffin block identification, a pushing invasive pattern, a superficial adenoma malignum-like invasive pattern, a MELF invasive pattern, a diffuse 'spotty' pattern of myoinvasive tumour, fibroblastic or stromal smooth muscle metaplasia, etc<sup>39,59-61</sup>.

**S3.09 Lymphovascular invasion by neoplastic cells both at the interface of tumour with the normal myometrium and more distantly must be recorded.**

CS3.09a The degree of lymphovascular involvement ( LVSI ) by neoplastic cells relates partly to the tumour invasive depth, and partly to the histological type. LVSI is an independent prognostic factor and often reflects the incidence of lymph node metastases, post-operative vaginal vault recurrence and survival<sup>62-63</sup>. With Type 1 carcinomas, LVSI at the interface of tumour with the normal myometrium is far

more common than involvement of the more distant vessels in the deep myometrium, the cervix, parametrium or ovarian hilum. Type 2 carcinomas may show a different pattern of tumour spread.

**S3.10 Involvement of the cervical tissues must be recorded.**

CS3.10a Occasionally neoplastic endometrial cells replace the normal endocervical glandular cells and may or may not be in continuity with the endometrial tumour mass. In these cases the underlying basement membrane remains intact. Such mucosal involvement has no prognostic significance but on occasions, in particular with "intraepithelial serous carcinoma", has been misinterpreted as *in situ* adenocarcinoma of the cervix. This histological finding may reflect either multicentric tumour origin or spontaneous tumour implantation by carcinoma cells transiting the cervix.

In contrast stromal invasion by endometrial carcinoma increases the risk of pelvic lymph node metastases. The depth of stromal invasion is measured from the cervical surface epithelium to the deepest infiltrative focus and is most reliably recorded using a calibrated ocular micrometer. Both the absolute invasive depth in mm and the thickness of the normal cervical wall (i.e. to the deep cervical-paracervical interface, and not the surgical plane of resection) must be recorded (as with primary cervical carcinomas). Some invasive tumours may represent tumour infiltration in-continuity with the endometrial tumour, some may represent metastases and others independent synchronous carcinomas<sup>64</sup>. Conspicuous vascular involvement favours lymphohaematogeneous metastasis. Occasionally, endometrial carcinomas involving the cervical stroma may show a deceptive pattern of invasion which can mimic primary cervical carcinoma or a benign process. At times the relative depth of invasion may even be greater in the cervical component of the tumour than in the myometrium and the invasive depth is no guide as to the site of tumour origin<sup>65</sup>. In the latter instance, particularly if the patient is young, consider the possibility of Lynch syndrome (HNPCC) and MSI studies may be considered.

**S3.11 Any residual non-tumourous endometrium must be sampled and the findings recorded.**

CS3.11a Since many endometrioid carcinomas are related to prior oestrogen exposure, the residual endometrium must be checked for endometrial hyperplasia (typical or atypical) and multicentric synchronous multicentric carcinomas. In all cases of multicentric carcinoma, the histological type, extent and involved sites must be recorded.

In serous and clear cell carcinomas the adjacent endometrium is usually atrophic. However it may be microscopically involved by a putative precursor lesion, serous intraepithelial carcinoma, or endometrial glandular dysplasia of serous or clear cell type<sup>66-68</sup>.

G3.03 Any additional relevant microscopic comments should be recorded.

## 4 Ancillary studies findings

This includes both histochemical and immunohistochemical stains. Recently several comprehensive publications on the use of immunohistochemical tests (IHC) in gynaecological cancers have appeared<sup>69-71</sup>. IHC has been mostly used in the female genital tract (FGT) for tumour classification rather than prognostic or predictive reasons and, as elsewhere, an immunopanel with high discriminating value is more reliable than a single antibody test. IHC does not distinguish benign from malignant tumours in any known circumstance. Of all the tumours arising in the FGT, those arising in the endometrium have least benefitted from the use of IHC.

- G4.01 The results of any histochemical stains used to assist in diagnosis should be recorded.
- G4.02 The results of any immunohistochemical stains used to assist in diagnosis should be recorded.

## 5 Synthesis and overview

Information that is synthesized from multiple modalities and therefore cannot reside solely in any one of the preceding chapters is described here. For example, tumour stage is synthesized from multiple classes of information – clinical, macroscopic and microscopic.

Overarching case comment is synthesis in narrative form. Although it may not necessarily be required in any given report, the provision of the facility for overarching commentary in a cancer report is essential.

By definition, synthetic elements are inferential rather than observational, often representing high-level information that is likely to form part of the 'diagnostic summary' section in the final formatted report.

### **S5.01 The pathological stage must be recorded.**

- CS5.01a Staging is a classification system that provides information regarding the anatomical extent of a tumour based on attributes that encompass the natural behaviour of the tumour.
- CS5.01b See Appendix 5 for details of the FIGO staging for endometrial cancer (2008) and Appendix 6 and 7 for the 2010 AJCC cancer staging system<sup>6</sup>.
- CS5.01c The reporting pathologist can only offer a tumour stage based on the limited material which they have personally reported. In general the operating surgeon will prove more reliable in formatting the correct tumour stage and after consideration of the clinical history, other surgical findings and the results of additional investigations. In summary the pathologist can give a reliable T stage but the N and M stages may have to await the outcome of a multidisciplinary meeting. In addition the assessment of residual tumour status by the pathologist can only be inferred from the accompanying clinical notes and the margin status and may be unreliable. The 'p' subscript refers to evidence based on histopathological examination and the 'c' subscript refers to evidence obtained from clinical, surgical or non-intrusive investigations. The use of both subscripts together in the N, M or R provides reassurance as to the reliability of the staging in any particular patient.

### **S5.02 The year of publication and edition of the cancer staging system used in S5.01 must be included in the report.**

- G5.01 Residual tumour status (i.e. involvement of surgical margins and excluding metastatic disease) should be recorded.
  - CG5.01a Residual tumour (R) is a TNM descriptor used to categorise the absence or presence of residual tumour after initial surgery.
  - CG5.01b The R categories for the primary tumour site<sup>6</sup> are as follows:
    - RX: Presence of residual tumour cannot be assessed
    - RO: No residual tumour

R1: Microscopic residual tumour  
R2: Macroscopic residual tumour.

G5.02 The 'diagnostic summary' section of the final formatted report should include:

- a. operative procedure/specimen type (S1.03)
- b. tumour type (S3.06)
- c. tumour stage (S5.01)
- d. residual tumour status (G5.01)

**S5.03 The reporting system must provide a field for free text or narrative in which the reporting pathologist can give overarching case comment.**

CS5.03a This field may be used, for example, to:

- discuss the significance of ancillary tests
- discuss any noteworthy prognostic features
- express any diagnostic subtlety or nuance that is beyond synoptic capture
- document further consultation or results still pending.

CS5.03b Use of this field is at the discretion of the reporting pathologist.

## 6 Structured checklist

The following checklist includes the standards and guidelines for this protocol which must be considered when reporting, in the simplest possible form. The summation of all 'Standards' is equivalent to the 'minimum dataset' for endometrial cancer. For emphasis, standards (mandatory elements) are formatted in bold font.

**S6.01 The structured checklist provided may be modified as required but with the following restrictions:**

- a. **All standards and their respective naming conventions, definitions and value lists must be adhered to.**
- b. **Guidelines are not mandatory but are recommendations and where used, must follow the naming conventions, definitions and value lists given in the protocol.**

G6.01 The order of information and design of the checklist may be varied according to the laboratory information system (LIS) capabilities.

CG6.01a Where the LIS allows dissociation between data entry and report format, the structured checklist is usually best formatted to follow pathologist workflow. In this situation, the elements of synthesis or conclusions are necessarily at the end. The report format is then optimised independently by the LIS.

CG6.01b Where the LIS does not allow dissociation between data entry and report format, (for example where only a single text field is provided for the report), pathologists may elect to create a checklist in the format of the final report. In this situation, communication with the clinician takes precedence and the checklist design is according to principles given in Chapter 7.

G6.02 Where the checklist is used as a report template (see G6.01), the principles in Chapter 7 and Appendix 2 apply.

CG6.02a All extraneous information, tick boxes and unused values should be deleted.

G6.03 Additional comment may be added to an individual response where necessary to describe any uncertainty or nuance in the selection of a prescribed response in the checklist. Additional comment is not required where the prescribed response is adequate.

## Clinical information and surgical handling

**S1.01 Patient name** \_\_\_\_\_

**Date of birth** \_\_\_\_\_

**Sex** \_\_\_\_\_

**Identification and contact details of requesting doctor** \_\_\_\_\_

**Date of request** \_\_\_\_\_

**Ethnicity:**

**Aboriginal or Torres Strait Islander** \_\_\_\_\_

**Other ethnicity** \_\_\_\_\_

**Unknown** \_\_\_\_\_

**G1.01 Patient identifiers (eg MRN, IHI, NHI)** \_\_\_\_\_

\_\_\_\_\_

**S1.02 Pathology accession number** \_\_\_\_\_

**S1.03 Principal clinician involved in the patient's care** \_\_\_\_\_

**S1.04 Operative procedure/ specimen:**

**Total hysterectomy** \_\_\_\_\_

**Subtotal hysterectomy** \_\_\_\_\_

**Radical hysterectomy** \_\_\_\_\_

**Accompanying specimens** \_\_\_\_\_

\_\_\_\_\_

\_\_\_\_\_

G1.04 Clinical diagnosis/ differential diagnoses \_\_\_\_\_  
\_\_\_\_\_  
\_\_\_\_\_

G1.05 Details of previous biopsies & cytology results (include testing laboratory) \_\_\_\_\_  
\_\_\_\_\_  
\_\_\_\_\_

G1.06 Details of any previous or current treatment of the present tumour \_\_\_\_\_  
\_\_\_\_\_  
\_\_\_\_\_

G1.07 Details of any other prior cancer diagnosis \_\_\_\_\_  
\_\_\_\_\_  
\_\_\_\_\_

G1.08 Details of any family history of cancer \_\_\_\_\_  
\_\_\_\_\_  
\_\_\_\_\_

**S1.05 Metastatic disease?**

**Not stated** \_\_\_\_\_

**Absent** (on both clinical & operative grounds) \_\_\_\_\_

**Present:** \_\_\_\_\_pre-operative

\_\_\_\_\_intra-operative

If present, give details

---

---

---

S1.06 Post-operative residual tumour:

Not stated

Absent

Present

If present, give details

---

---

---

G1.09 Surgeon's specific remarks

---

---

---

## Macroscopic findings

S2.04 Lymph nodes:

Site 1

---

description

---

---

---

total number of nodes

---

Max. diameter/  
size range

\_\_\_\_\_ to \_\_\_\_\_ mm

Site 2

---

**description** \_\_\_\_\_

\_\_\_\_\_

\_\_\_\_\_

**total number of nodes** \_\_\_\_\_

**Max. diameter/size range** \_\_\_\_\_to\_\_\_\_\_ mm

**Site 3**

\_\_\_\_\_

**description** \_\_\_\_\_

\_\_\_\_\_

\_\_\_\_\_

**total number of nodes** \_\_\_\_\_

**Max. diameter/size range** \_\_\_\_\_to\_\_\_\_\_ mm

**Site 4**

\_\_\_\_\_

**description** \_\_\_\_\_

\_\_\_\_\_

\_\_\_\_\_

**total number of nodes** \_\_\_\_\_

**Max. diameter/size range** \_\_\_\_\_to\_\_\_\_\_ mm

**Site 5**

\_\_\_\_\_

**description** \_\_\_\_\_

\_\_\_\_\_

\_\_\_\_\_

**total number of nodes** \_\_\_\_\_

**Max. diameter/size range** \_\_\_\_\_to\_\_\_\_\_ mm



**Site 2**

**dimensions** \_\_\_\_X\_\_\_\_X\_\_\_\_ mm

**description**

**Site 3**

**dimensions** \_\_\_\_X\_\_\_\_X\_\_\_\_ mm

**description**

**S2.07 Ovaries:**

**Right ovary:**

**surface**

**dimensions** \_\_\_\_X\_\_\_\_X\_\_\_\_ mm

**description**

**Left ovary:**

**surface**

**dimensions** \_\_\_\_X\_\_\_\_X\_\_\_\_ mm

**description**

**S2.08 Fallopian tubes:**

**Right tube:**

**dimensions** \_\_\_X\_\_\_ mm  
(Length x max. diameter)

**description** \_\_\_\_\_  
\_\_\_\_\_  
\_\_\_\_\_

**Left tube:**

**dimensions** \_\_\_X\_\_\_ mm  
(Length x max. diameter)

**description** \_\_\_\_\_  
\_\_\_\_\_  
\_\_\_\_\_

**S2.09 External appearance of uterus**

**Uterus received:**

**intact** \_\_\_

**opened** \_\_\_

**Serosal surface** \_\_\_\_\_

**S2.10 Weight of uterus** \_\_\_ g

**S2.11 Measurements of uterus** \_\_\_mm midline fundal-serosa to  
ectocervix

\_\_\_mm max. intercornual

\_\_\_mm max. anterior to posterior

**Gross description** \_\_\_\_\_  
\_\_\_\_\_  
\_\_\_\_\_

**S2.12 Site of tumour:**

**anterior endometrium** \_\_\_

**posterior endometrium** \_\_\_



S2.14 Gross depth of maximal myometrial invasion \_\_\_\_\_mm

Thickness of normal (uninvolved) myometrial wall \_\_\_\_\_mm

S2.15 Cervical tissues:

Description \_\_\_\_\_  
\_\_\_\_\_

If tumour present :

Dimensions \_\_\_\_\_x\_\_\_\_\_x\_\_\_\_\_ mm

Distance of cervical tumour from the inferior surgical margin \_\_\_\_\_mm

Max. depth of cervical wall invasion \_\_\_\_\_mm

Thickness of normal (uninvolved) cervical wall \_\_\_\_\_mm

G2.06 Other relevant macroscopic comments \_\_\_\_\_  
\_\_\_\_\_

### Microscopic findings

S3.01 Lymph node involvement by tumour:

Site 1 \_\_\_\_\_

Number of nodes involved by tumour \_\_\_\_\_

Total number of nodes resected \_\_\_\_\_

Max. dimension of the metastasis or size range \_\_\_\_\_to\_\_\_\_\_ mm

Extranodal spread:

Absent \_\_\_\_\_

	Present	___
Site 2	<hr/>	
	Number of nodes involved by tumour	___
	Total number of nodes resected	___
	Max. dimension of the metastasis or size range	___ to ___ mm
	Extranodal spread:	
	Absent	___
	Present	___
Site 3	<hr/>	
	Number of nodes involved by tumour	___
	Total number of nodes resected	___
	Max. dimension of the metastasis or size range	___ to ___ mm
	Extranodal spread:	
	Absent	___
	Present	___
Site 4	<hr/>	
	Number of nodes involved by tumour	___
	Total number of nodes resected	___
	Max. dimension of the metastasis or size range	___ to ___ mm
	Extranodal spread:	
	Absent	___
	Present	___
Site 5	<hr/>	

Number of nodes involved by tumour \_\_\_\_\_  
Total number of nodes resected \_\_\_\_\_  
Max. dimension of the metastasis or size range \_\_\_\_\_ to \_\_\_\_\_ mm

Extranodal spread:  
Absent \_\_\_\_\_  
Present \_\_\_\_\_

Site 6 \_\_\_\_\_

Number of nodes involved by tumour \_\_\_\_\_  
Total number of nodes resected \_\_\_\_\_  
Max. dimension of the metastasis or size range \_\_\_\_\_ to \_\_\_\_\_ mm

Extranodal spread:  
Absent \_\_\_\_\_  
Present \_\_\_\_\_

Site 7 \_\_\_\_\_

Number of nodes involved by tumour \_\_\_\_\_  
Total number of nodes resected \_\_\_\_\_  
Max. dimension of the metastasis or size range \_\_\_\_\_ to \_\_\_\_\_ mm

Extranodal spread:  
Absent \_\_\_\_\_  
Present \_\_\_\_\_

S3.02 Omental involvement:

Tumour free \_\_\_\_\_  
Involved \_\_\_\_\_

**S3.03 Peritoneal involvement:**  
If involved describe the nature of tumour involvement \_\_\_\_\_  
Tumour free \_\_\_\_\_  
Involved \_\_\_\_\_

**S3.04 Ovarian involvement:**  
If involved describe the nature of tumour involvement \_\_\_\_\_

**S3.05 Fallopian tubal involvement:**  
Tumour free \_\_\_\_\_  
Involved \_\_\_\_\_

If involved describe the nature of tumour involvement \_\_\_\_\_

**S3.06 Histological tumour type:**  
Endometrioid adenocarcinoma \_\_\_\_\_  
and variant \_\_\_\_\_  
Mucinous adenocarcinoma \_\_\_\_\_  
Serous carcinoma \_\_\_\_\_  
Clear cell carcinoma \_\_\_\_\_  
Carcinosarcoma \_\_\_\_\_  
Undifferentiated carcinoma \_\_\_\_\_  
Other Tumour Type \_\_\_\_\_

Mixed types of \_\_\_\_\_ and \_\_\_\_\_  
endometrial carcinomas  
\_\_\_\_\_ and \_\_\_\_\_ relative %

**S3.07 Histological grade for  
endometrioid carcinomas:**

FIGO                      Grade 1    \_\_\_\_\_  
                                    Grade 2    \_\_\_\_\_  
                                    Grade 3    \_\_\_\_\_  
                                    Grading not applicable    \_\_\_\_\_

Grading system used:

FIGO    \_\_\_\_\_

Other (specify) \_\_\_\_\_

G3.02                      Year of publication: \_\_\_\_\_

**S3.08 Maximum microscopic depth  
of myometrial invasion**

\_\_\_\_\_mm invasive depth  
(in histologic slide No: \_\_\_\_\_)

out of \_\_\_\_\_ mm normal myometrial  
wall thickness

**S3.09 Lymphovascular invasion:**

Absent    \_\_\_\_\_

present and at the tumour  
interface    \_\_\_\_\_

present and within the  
myometrium remote to the  
tumour interface    \_\_\_\_\_mm (maximum) from tumour face

**S3.10 Cervical involvement:**

Involvement of cervical  
mucosa only:

Absent    \_\_\_\_\_

Present & in-  
continuity    \_\_\_\_\_

Present &  
separate    \_\_\_\_\_

**Involvement of cervical stroma:**

Absent

Present & in-continuity

Present & separate

If present:  mm (maximum) invasive depth  
(in histologic slide No: )

out of  mm normal cervical wall thickness

**Cervical vascular involvement:**

Absent

Present

**S3.11 Residual non-tumourous endometrium:**

Atrophic/Cycle phase

Hyperplastic

Atypical hyperplastic

Description e.g. polyps \_\_\_\_\_  
\_\_\_\_\_

***In situ* carcinoma:**

Absent

Present

**Multicentric/  
multifocal carcinoma:**

Absent

Present

Histological type \_\_\_\_\_

Extent \_\_\_\_\_

**Sites** \_\_\_\_\_

G3.03 Other relevant microscopic comments  
\_\_\_\_\_  
\_\_\_\_\_  
\_\_\_\_\_

### Ancillary test findings

G4.01 Histochemical stains:  
\_\_\_\_\_  
\_\_\_\_\_  
\_\_\_\_\_

G4.02 Immunohistochemical stains:  
  
Antibodies:  
  
Positive antibodies \_\_\_\_\_  
  
Negative antibodies \_\_\_\_\_  
  
Equivocal antibodies \_\_\_\_\_  
  
Interpretation \_\_\_\_\_  
  
Clinical significance \_\_\_\_\_

### Synthesis and overview

S5.01 Tumour stage (FIGO):  
  
I \_\_\_\_\_  
  
IA \_\_\_\_\_  
  
IB \_\_\_\_\_  
  
II \_\_\_\_\_  
  
IIIA \_\_\_\_\_  
  
IIIB \_\_\_\_\_  
  
IIIC1 \_\_\_\_\_

IIIC2 \_\_\_\_

IVA \_\_\_\_

IVB \_\_\_\_

**Pathological Tumour stage  
(pTNM):**

T \_\_\_\_

N \_\_\_\_

M \_\_\_\_

**S5.02 Year of publication and  
edition of cancer staging  
system**

\_\_\_\_\_

G5.01 Residual tumour status:

RX \_\_\_\_

R0 \_\_\_\_

R1 \_\_\_\_

R2 \_\_\_\_

G5.02 Diagnostic summary

\_\_\_\_\_

\_\_\_\_\_

\_\_\_\_\_

**S5.03 Other relevant information  
and comments**

\_\_\_\_\_

\_\_\_\_\_

\_\_\_\_\_

## 7 Formatting of pathology reports

Good formatting of the pathology report is essential to optimise communication with the clinician, and will be an important contributor to the success of cancer reporting protocols. The report should be formatted to provide information clearly and unambiguously to the treating doctors, and should be organised with their use of the report in mind. In this sense, the report differs from the structured checklist, which is organised with the pathologists' workflow as a priority.

Uniformity in the format as well as in the data items of cancer reports between laboratories makes it easier for treating doctors to understand the reports; it is therefore seen as an important element of the systematic reporting of cancer.

Please see Appendix 2 for further guidance.

# Appendix 1 Pathology request form for endometrial cancer

**S1.01 Patient name** \_\_\_\_\_

**Date of birth** \_\_\_\_\_

**Sex** \_\_\_\_\_

**Identification and contact details of requesting doctor** \_\_\_\_\_

**Date of request** \_\_\_\_\_

**Ethnicity:**

**Aboriginal or Torres Strait Islander** \_\_\_\_\_

**Other ethnicity** \_\_\_\_\_

**Unknown** \_\_\_\_\_

**G1.01 Patient identifiers (eg MRN, IHI, NHI)** \_\_\_\_\_

\_\_\_\_\_

**S1.03 Principal clinician involved in the patient's care** \_\_\_\_\_

**S1.04 Operative procedure/ specimen:**

**Total hysterectomy** \_\_\_\_\_

**Subtotal hysterectomy** \_\_\_\_\_

**Radical hysterectomy** \_\_\_\_\_

**Accompanying specimens** \_\_\_\_\_

\_\_\_\_\_

\_\_\_\_\_

G1.04 Clinical diagnosis/ differential diagnoses \_\_\_\_\_  
\_\_\_\_\_  
\_\_\_\_\_

G1.05 Details of previous biopsies & cytology results (include testing laboratory) \_\_\_\_\_  
\_\_\_\_\_  
\_\_\_\_\_

G1.06 Details of any previous or current treatment of the present tumour \_\_\_\_\_  
\_\_\_\_\_  
\_\_\_\_\_

G1.07 Details of any other prior cancer diagnosis \_\_\_\_\_  
\_\_\_\_\_  
\_\_\_\_\_

G1.08 Details of any family history of cancer \_\_\_\_\_  
\_\_\_\_\_  
\_\_\_\_\_

**S1.05 Metastatic disease?**

**Absent** (on both clinical & operative grounds) \_\_\_\_\_

**Present:** \_\_\_\_\_pre-operative

\_\_\_\_\_intra-operative

**If present, give details** \_\_\_\_\_  
\_\_\_\_\_  
\_\_\_\_\_

**S1.06 Post-operative residual tumour:**

**Absent** \_\_\_\_\_

**Present** \_\_\_\_\_

**If present, give details**

---

---

---

**G1.09 Surgeon's specific remarks**

---

---

---

## Appendix 2 Guidelines for formatting of a pathology report

### Layout

Headings and spaces should be used to indicate subsections of the report, and heading hierarchies should be used where the LIS allows it. Heading hierarchies may be defined by a combination of case, font size, style and, if necessary, indentation.

- Grouping like data elements under headings and using 'white space' assists in rapid transfer of information<sup>72</sup>.

Descriptive titles and headings should be consistent across the protocol, checklist and report.

When reporting on different tumour types, similar layout of headings and blocks of data should be used, and this layout should be maintained over time.

- Consistent positioning speeds data transfer and, over time, may reduce the need for field descriptions or headings, thus reducing unnecessary information or 'clutter'.

Within any given subsection, information density should be optimised to assist in data assimilation and recall.

- Configuring reports in such a way that they 'chunk' data elements into a single unit will help to improve recall for the clinician<sup>72</sup>.
- 'Clutter' should be reduced to a minimum<sup>72</sup>. Thus, information that is not part of the protocol (eg billing information, Snomed codes, etc) should not appear on the reports or should be minimised.
- Injudicious use of formatting elements (eg too much bold, underlining or use of footnotes) also increases clutter and may distract the reader from the key information.

Where a structured report checklist is used as a template for the actual report, any values provided in the checklist but not applying to the case in question must be deleted from the formatted report.

Reports should be formatted with an understanding of the potential for the information to 'mutate' or be degraded as the report is transferred from the LIS to other health information systems.

As a report is transferred between systems:

- text characteristics such as font type, size, bold, italics and colour are often lost
- tables are likely to be corrupted as vertical alignment of text is lost when fixed font widths of the LIS are rendered as proportional fonts on screen or in print
- spaces, tabs and blank lines may be stripped from the report, disrupting the formatting
- supplementary reports may merge into the initial report.

# Appendix 3 Example pathology report for endometrial cancer

<b>Tshen, Georgina W.</b> C/O Paradise Close Wreck Bay Resort Nar Nar Goon East, 3181  Female  DOB 1/7/1951 MRN FMC1096785	Lab Ref: <b>10/P28460</b> Referred: 30/8/2010	Copy to: <b>Dr G. Grey</b> Rainforest Cancer Centre. 46 Smith Road, Woop Woop, 3478	Referred by: <b>Dr V. Smith</b> Suite 3, AJC Medical Centre, Bunyip Crescent Nar Nar Goon West, 3182
--	--	--	---

## ENDOMETRIAL CANCER STRUCTURED REPORT

Page 1 of 3

### Diagnostic Summary

Total hysterectomy, pelvic lymph nodes L & R:

**Endometrioid adenocarcinoma, grade 2 (FIGO), Stage 1A (FIGO), pT1a, cpNO, cpMO (TNM), cpRO**

Comment: Bulky uterus, enlarged pelvic nodes, previous D&C.

### Supporting Information

#### CLINICAL

<b>Specimens:</b>	Uterus with attached cervix, left & right pelvic lymph nodes
<b>Clinical diagnosis:</b>	Atypical endometrial hyperplasia on previous curette
<b>Previous diagnosis:</b>	Complex atypical endometrial hyperplasia. (St Barnabas Pathology. July 2010).
<b>Prev/current treatment:</b>	On progestagens for 6 months for PMB
<b>Other cancer diagnosis:</b>	None.
<b>Family history:</b>	Breast cancer in mother last year.
<b>Metastatic disease:</b>	None on prior investigations or found during surgery.
<b>Post-operative residual tumour:</b>	None found during surgery.

#### MACROSCOPIC

##### Lymph nodes

###### (1). "Left pelvic lymph nodes":

Description:	20x17 mm mass of fatty tissue. On sectioning of the nodes no obvious abnormalities could be found on gross examination.
Total number nodes:	7.
Max. diameter size range:	2 to 5mm

###### (2). "Right pelvic lymph nodes":

Description:	25x11 mm mass of fatty tissue. On sectioning of the nodes no obvious abnormalities could be found on gross examination.
Total number nodes:	9.
Max. diameter size range:	2 to 5mm

Omentum	Not received
Peritoneal biopsies	Not received
Ovaries	Not received
Fallopian tubes	Not received
Uterus	
<b>Received:</b>	intact
<b>Serosal surface:</b>	The uterine serosa is normal.
<b>Weight:</b>	250g
<b>Measurements of uterus:</b>	
<b>Midline fundal-serosa to ectocervix</b>	76mm
<b>Max. intercornual</b>	69mm
<b>Max. anterior to posterior</b>	55mm
<b>Gross description:</b>	A fresh uterus with attached cervix. On opening the specimen a large exophytic, friable and haemorrhagic mass is found to replace the entire endometrium. No fallopian tubes or vaginal cuff are attached.
<b>Site of tumour:</b>	anterior, posterior and fundal endometrium
<b>Tumour dimensions:</b>	35x25x25 mm
<b>Gross depth of max. myometrial invasion:</b>	4mm (estimated) out of a normal myometrial thickness of 15mm
<b>Cervical tissue:</b>	No tumour involvement
<b>Tumour distance from the inferior surgical margin:</b>	29 mm.

#### MICROSCOPIC

##### Lymph nodes:

###### (1) Left pelvic

**Nodes involved by tumour:** 0 out of 7 resected nodes.

**Max. dimension/size range:** N/A (No metastasis)

###### (2) Right pelvic

**Nodes involved by tumour:** 0 out of 9 resected nodes.

**Max. dimension/size range:** N/A (No metastasis)

<b>Histological Tumour type:</b>	Endometrioid adenocarcinoma
<b>Grade:</b>	Grade 2 (FIGO)
<b>Max. depth of myometrial invasion:</b>	4 mm invasive depth out of a normal myometrial thickness of 15mm (slide 1.12)
<b>Lymphovascular invasion:</b>	Present and only at the tumour-myometrial interface (slide 1.14)
<b>Cervical involvement:</b>	Absent

<b>Residual non-tumourous endometrium:</b>	Atrophic
Atypical hyperplasia	Absent
Multifocal carcinoma	Absent
<i>in situ</i> carcinoma	Absent

**ANCI LLARY TESTS**

No immunohistochemistry or other special stains were performed.

*Reported by Dr Bernard Beckstein*

Authorised 4/9/2010

# **Appendix 4      WHO histological classification (2003)<sup>5</sup>**

## **Epithelial tumours**

### **Endometrial carcinoma**

- Endometrioid adenocarcinoma
  - Variant with squamous differentiation
  - Villoglandular variant
  - Secretory variant
  - Ciliated cell variant
- Mucinous adenocarcinoma
- Serous adenocarcinoma
- Clear cell adenocarcinoma
- Mixed cell adenocarcinoma
- Squamous cell carcinoma
- Transitional cell carcinoma
- Small cell carcinoma
- Undifferentiated carcinoma
- Others

### **Mixed epithelial and mesenchymal tumours**

- Carcinosarcoma (malignant mullerian mixed tumour, metaplastic carcinoma)

© World Health Organisation. Reproduced with permission.

## Appendix 5 FIGO cancer staging system<sup>6</sup>

### Carcinoma of the Endometrium (2008)

<b>Stage I*</b>	Tumor confined to the corpus uteri
<b>IA*</b>	No or less than half myometrial invasion
<b>IB*</b>	Invasion equal to or more than half of the myometrium
<b>Stage II*</b>	Tumor invades cervical stroma, but does not extend beyond the uterus**
<b>Stage III*</b>	Local and/or regional spread of the tumor
<b>IIIA*</b>	Tumor invades the serosa of the corpus uteri and/or adnexae#
<b>IIIB*</b>	Vaginal and/or parametrial involvement#
<b>IIIC*</b>	Metastases to pelvic and/or para-aortic lymph nodes#
<b>IIIC1*</b>	Positive pelvic nodes
<b>IIIC2*</b>	Positive para-aortic lymph nodes with or without positive pelvic lymph nodes
<b>Stage IV*</b>	Tumor invades bladder and/or bowel mucosa, and/or distant metastases
<b>IVA*</b>	Tumor invasion of bladder and/or bowel mucosa
<b>IVB*</b>	Distant metastases, including intra-abdominal metastases and/or inguinal lymph nodes

\* Either G1, G2, or G3.

\*\*Endocervical glandular involvement only should be considered as Stage I and no longer as Stage II.

# Positive cytology has to be reported separately without changing the stage.

Reprinted from the International Journal of Gynecology & Obstetrics 105:103-104 FIGO Committee on Gynecological Cancer (2009). Revised FIGO staging for carcinoma of the vulva, cervix, and endometrium with permission from Elsevier<sup>73</sup>.

## Appendix 6      2010 AJCC T Stage

Primary Tumour (T) (Surgical-Pathologic Findings)		
<i>TNM Categories</i>	<i>FIGO stages</i>	
TX		Primary tumour cannot be assessed
T0		No evidence of primary tumour
Tis*		Carcinoma <i>in situ</i> (preinvasive carcinoma)
T1	I	Tumour confined to corpus uteri
T1a	IA	Tumour limited to endometrium or invades less than one-half of the myometrium
T1b	IB	Tumour invades one-half or more of the myometrium
T2	II	Tumour invades stromal connective tissue of the cervix but does not extend beyond uterus**
T3a	IIIA	Tumour involves serosa and /or adnexa (direct extension or metastasis)
T3b	IIIB	Vaginal involvement (direct extension or metastasis) or parametrial involvement.
T4	IVA	Tumour invades bladder mucosa and /or bowel mucosa (bullous oedema is not sufficient to classify a tumour as T4)

\* Note: FIGO no longer includes Stage 0(Tis)

\*\* Endocervical glandular involvement only should be considered Stage I and not as Stage II.

Used with the permission of the American Joint Committee on Cancer (AJCC), Chicago, Illinois. The original source for this material is the AJCC Cancer Staging Manual, Seventh Edition (2010) published by Springer Science and Business Media LLC, [www.springerlink.com](http://www.springerlink.com).

## Appendix 7 2010 AJCC N and M Stages

<b>Regional Lymph Nodes (N)</b>		
<i>TNM Categories</i>	<i>FIGO stages</i>	
NX		Regional lymph nodes cannot be assessed
N0		No regional lymph node metastasis
N1	IIIC1	Regional lymph nodes metastasis to pelvic lymph nodes
N2	IIIC2	Regional lymph nodes metastasis to para-aortic lymph nodes, with or without positive pelvic lymph nodes.

<b>Distant Metastasis (M)</b>		
<i>TNM Categories</i>	<i>FIGO stages</i>	
M0		No distant metastasis
M1	IVB	Distant metastasis (includes metastasis to inguinal lymph nodes intraperitoneal disease, or lung, liver, or bone. It excludes metastasis to para-aortic lymph nodes, vagina, pelvic serosa, or adnexa.

### Anatomical Stage/Prognostic Groups

*Carcinomas\**

<b>Stage</b>	<b>T</b>	<b>N</b>	<b>M</b>
Stage 0**	Tis	N0	M0
Stage I	T1	N0	M0
Stage IA	T1a	N0	M0
Stage IB	T1b	N0	M0
Stage II	T2	N0	M0
Stage III	T3	N0	M0
Stage IIIA	T3a	N0	M0
Stage IIIB	T3b	N0	M0
Stage IIIC1	T1-T3	N1	M0
Stage IIIC2	T1-T3	N2	M0
Stage IVA	T4	Any N	M0

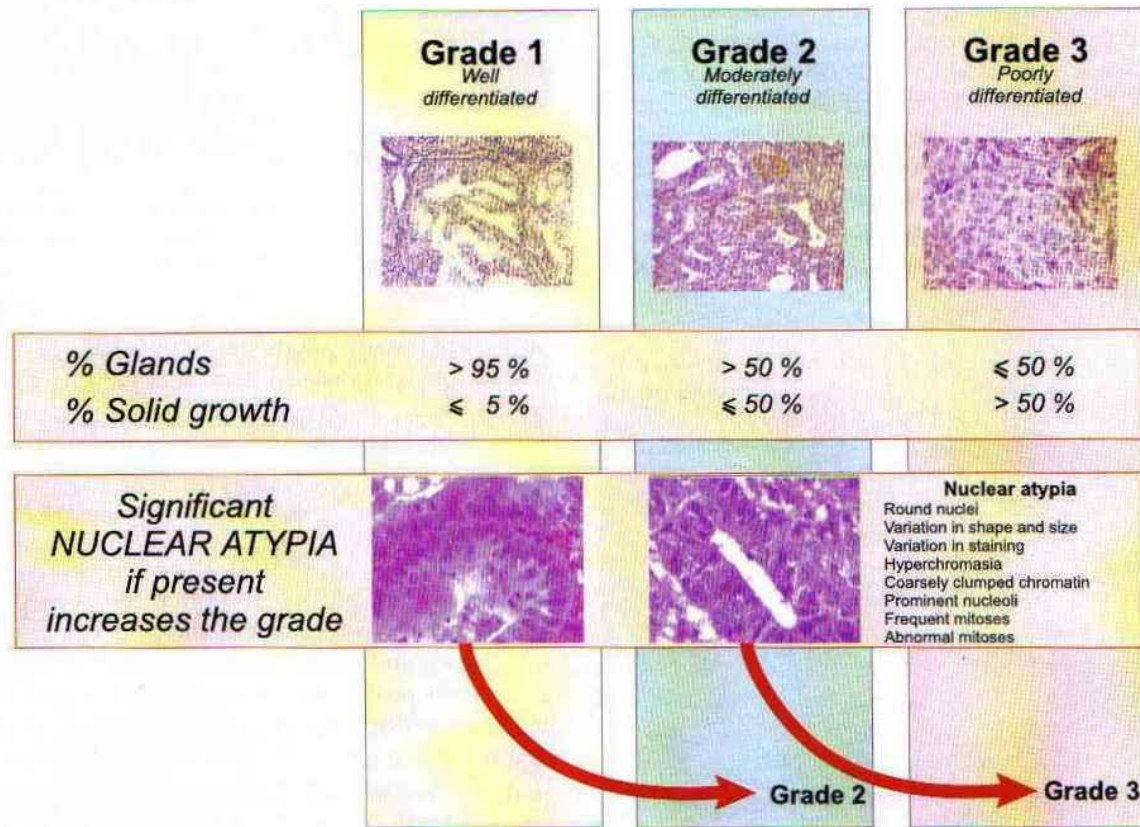
Stage IVB	Any T	Any N	M1
-----------	-------	-------	----

\* Carcinosarcomas should be staged as carcinoma

\*\*Note: FIGO no longer includes Stage 0(Tis)

Used with the permission of the American Joint Committee on Cancer (AJCC), Chicago, Illinois. The original source for this material is the AJCC Cancer Staging Manual, Seventh Edition (2010) published by Springer Science and Business Media LLC, [www.springerlink.com](http://www.springerlink.com).

## Appendix 8 Grading of endometrioid adenocarcinoma



**Figure A8.1** Grading of endometrial adenocarcinoma. The grade depends primarily on the architectural pattern, but significant nuclear atypia changes a grade 1 tumor to grade 2, and a grade 2 tumor to grade 3<sup>28</sup>.

Reprinted with permission from Robboy SJ, Anderson MC and Russell P (eds) *Pathology of the Female Reproductive Tract*, Figure 13.61 page 354. (2002), Churchill Livingstone.

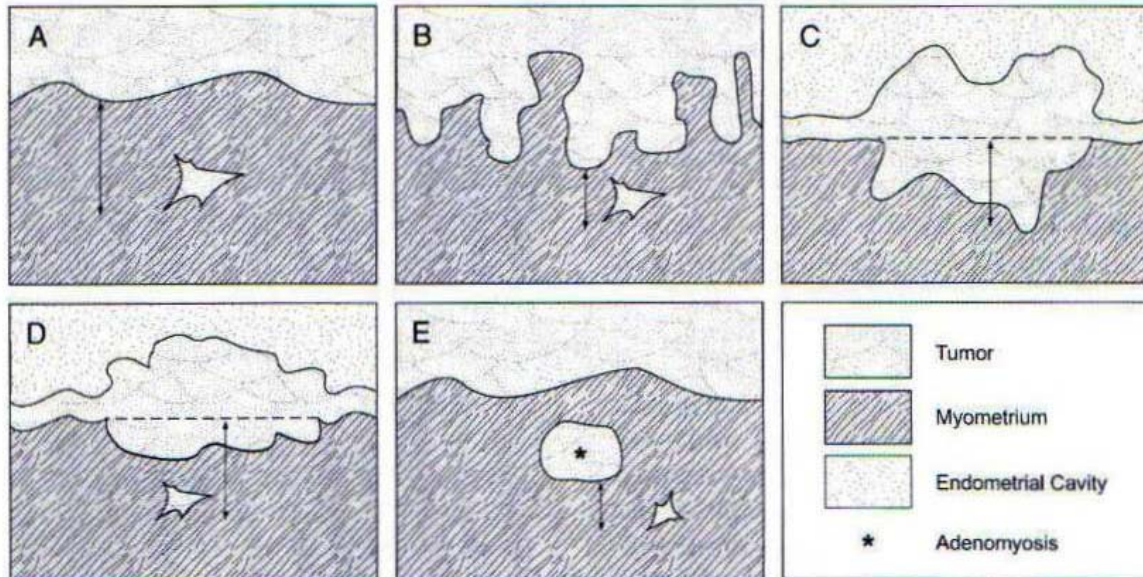
## Appendix 9 Nuclear grading of endometrioid adenocarcinoma

Grade 1	Grade 2	Grade 3
Oval or elongated	→	Round
Little variation in shape	→	Marked variation in shape
Little variation in size	→	Marked variation in size (some markedly enlarged)
Hypochromasia	→	Marked hyperchromasia (may be focal)
No variation in staining intensity	→	Marked variation in staining intensity
Evenly distributed chromatin	→	Coarsely clumped chromatin
Nucleoli not prominent	→	Prominent nucleoli
Sparse mitoses	→	Frequent mitoses with abnormal forms
Close together in radial fashion		Readily recognizable at low power

**Figure A9.1 Nuclear grading of endometrial carcinoma<sup>28</sup>**

Reprinted with permission from Robboy SJ, Anderson MC and Russell P (eds)  
*Pathology of the Female Reproductive Tract*, (2002), Churchill Livingstone. Table 13.4

## Appendix 10 Assessing microscopic depth of myometrial invasion



**Figure A10.1 Assessing DMI**<sup>39</sup>.

(A) Measurement of DMI in an uncomplicated case

(B) Measurement of DMI in a tumour with an irregular endomyometrial junction

(C) and (D) Measurement of DMI in exophytic tumours. The depth of invasion should be measured, not the tumour thickness

(E) A proposal for measuring the DMI in cases showing deeply placed invasive carcinoma in proximity to adenomyosis colonized by carcinoma. The distance between the adenomyosis/myometrial interface and the deepest extent of invasion tumour is measured.

Reproduced with permission from Ali A, Black D and Soslow R (2007). Difficulties in Assessing the Depth of Myometrial Invasion in Endometrial Carcinoma *Int J. Gynecol Pathology* 26: 155-123. Wolters Kluwer.

# References

- 1 Khalifa MA, Dodge J and Covens A et al (2003). Slide review in gynecologic oncology ensures completeness of reporting and diagnostic accuracy. *Gynecol Oncol* 90:425-430.
- 2 McCluggage WG (2002). Uterine carcinosarcomas (malignant mixed mullerian tumours) are metaplastic carcinomas. *Int. J. Gynecol. Cancer* 12:687-690.
- 3 Clarke BA and Gilks CB (2010 May). Endometrial carcinoma: controversies in histopathological assessment of grade and tumour cell type. *J Clin Pathol.* 63(5):410-415.
- 4 Jemal A, Murray T, Samuels A, Ghafoor A, Ward E and Thun MJ (2003). Cancer Statistics. *CA Cancer J Clin* 53:5-26.
- 5 WHO (World Health Organization) (2003). *World Health Organization Classification of Tumours. Pathology and Genetics of Tumours of the Breast and Female Genital Organs*. Tavassoli FA and Devilee P. IARC Press, Lyon.
- 6 Edge SE, Byrd DR, Compton CC, Fritz AG, Greene FL and Trotti A (eds) (2010). *AJCC Cancer Staging Manual 7th ed.*, New York, NY.: Springer.
- 7 Cancer Council Victoria (2010). Canstat: A digest of facts and figures on cancer No. 47.
- 8 Berek JS and Hacker NF (2010). *Gynecologic Oncology*. Wolters Kluwer; Lippincott Williams & Wilkins
- 9 Gehrig PA, Groben PA, Fowler WC Jr., Walton LA and Van Le L (2001). Noninvasive papillary serous carcinoma of the endometrium. *Obstet Gynecol* 97:153-157.
- 10 Rabban JT and Zaloudek CJ (2007). Minimal uterine serous carcinoma: current concepts in diagnosis and prognosis *Diagnostic Pathology* 39(1):125-133.
- 11 Altrabulsi B, Malpica A and Deavers MT et al (2005). Undifferentiated carcinoma of the endometrium. *Am J Surg Pathol* 2:1316-1321.
- 12 Sherman ME, Bitterman P, Rosenshein NB, Delgado G and Kurman RJ (1992). Uterine serous carcinoma *Am J Surg Pathol* 16:600-610.
- 13 Christopherson WM, Alberhasky RG and Connelly PJ (1982). Carcinoma of the endometrium: In a clinicopathologic study of clear cell carcinoma and secretory carcinoma. *Cancer* 49:1511-1516.

- 14 Cirisano FD, Robboy SF and Dodge RK et al (2000). The outcome of Stage I-II clinically and surgically staged papillary serous and clear cell endometrial cancers when compared with endometrioid carcinoma. *Gynecol. Oncol.* 77:55-63.
- 15 Wheeler DT, Bell KA and Kurman RJ (2000). Minimal serous uterine carcinoma: diagnosis and clinicopathologic correlation. *Am J Surg Pathol* 24:797-806.
- 16 Cross SS, Feeley KM and Angel CA (1998). The effect of four interventions on the informational content of histopathology reports of resected colorectal carcinomas. *Journal of Clinical Pathology* 51(6):481–482.
- 17 Mathers M, Shrimankar J, Scott D, Charlton F, Griffith C and Angus B (2001). The use of a standard proforma in breast cancer reporting. *Journal of Clinical Pathology* 54(10):809–811.
- 18 Srigley JR, McGowan T, MacLean A, Raby M, Ross J, Kramer S and Sawka C (2009). Standardized synoptic cancer pathology reporting: A population-based approach. *Journal of Surgical Oncology* 99(8):517–524.
- 19 Gill AJ, Johns AL, Eckstein R, Samra JS, Kaufman A, Chang DK, Merrett ND, Cosman PH, Smith RC, Biankin AV and Kench JG (2009). Synoptic reporting improves histopathological assessment of pancreatic resection specimens. *Pathology* 41(2):161–167.
- 20 CAP (College of American Pathologists) (2009). *Cancer protocols and checklists* Available from: <[http://www.cap.org/apps/cap.portal?\\_nfpb=true&cntvwrPtl\\_t\\_actionOverride=%2Fportlet%2FcontentViewer%2Fshow&\\_windowLabel=cntvwrPtl\\_t%7BactionForm.contentReference%7D=committees%2Fcancer%2Fcancer\\_protocols%2Fprotocols\\_index.html&\\_state=maximized&\\_pageLabel=cntvwr](http://www.cap.org/apps/cap.portal?_nfpb=true&cntvwrPtl_t_actionOverride=%2Fportlet%2FcontentViewer%2Fshow&_windowLabel=cntvwrPtl_t%7BactionForm.contentReference%7D=committees%2Fcancer%2Fcancer_protocols%2Fprotocols_index.html&_state=maximized&_pageLabel=cntvwr)> (Accessed 13 October 2009).
- 21 RCP (Royal College of Pathologists) (2009). *Datasets and tissue pathways* RCP Available from: <<http://www.rcpath.org/index.asp?PageID=254>> (Accessed 13th Oct 09).
- 22 RCPA (Royal College of Pathologists of Australasia) (2009). *Guidelines for Authors of Structured Cancer Pathology Reporting Protocols*. RCPA, Surry Hills, NSW.
- 23 RCPA (Royal College of Pathologists of Australasia) (2004). *The Pathology Request-Test-Report Cycle — Guidelines for Requesters and Pathology Providers*, RCPA, Surry Hills, NSW.

- 24 International Union against Cancer (UICC) (2009). *TNM Classification of Malignant Tumours*. Sobin L, Gospodarowicz M and C W. Wiley-Blackwell, Chichester, UK and Hoboken, New Jersey.
- 25 Wittekind C, Henson D, Hutter R and Sobin L (eds) (2001). *TNM Supplement: A Commentary on Uniform Use*, Wiley-Liss, New York.
- 26 Tworek JA (2008). Safety practices in surgical pathology: practical steps to reduce error in the pre-analytic, analytic, and post-analytic phases of surgical pathology. *Diagnostic Histopathology* 14(7):292-298.
- 27 Lester SC (2005). *Manual of Surgical Pathology, 2nd edition*. Elsevier Churchill Livingstone.
- 28 Robboy SJ, Anderson MC and Russell P (eds) (2008). *Pathology of the Female Reproductive Tract*, Churchill Livingstone.
- 29 Feeley C and Rasbridge S (2007). Non-neoplastic nuclear atypia in endometrial epithelium in post menopausal women on hormonal therapy. *Histopathology* 50(7).
- 30 Clement PB and Young RH (2002). Endometrioid Carcinoma of the Uterine Corpus: A review of its pathology with emphasis on recent advances and problematic aspects. *Advances in Anatomic Pathology* 9(3):145-184.
- 31 Wheeler DT, Bristow RE and Kurman RJ (2007). Histologic alterations in endometrial hyperplasia and well-differentiated carcinoma treated with progestins. *Am J Surg Pathol* 31:988-998.
- 32 Karamurzin Y and Rutgers JKL (2009). DNA Mismatch Repair Deficiency in Endometrial Carcinoma. *Int. J. Gynecol. Pathology* 28:239-255.
- 33 Karlan BY, Berchuck A and Mutch D (2007). The Role of Genetic Testing for Cancer Susceptibility in Gynecologic Practice. *Obstetrics and Gynecology* 110(1):155-167.
- 34 Manchanda R, Menon U, Michaelson-Cohen R, Beller U and Jacobs I (2009). Hereditary non-polyposis colorectal cancer or Lynch syndrome: the gynaecological perspective. *Curr opin Obstet Gynecol* 21:31-38.
- 35 Walsh MD, Cummings MC, Buchanan DD, Dambacher WM, Arnold S, McKeone AS and Byrnes R et al (2008). Molecular, pathologic, and clinical features of early-onset endometrial cancer: identifying presumptive Lynch syndrome patients. *Clin. Cancer Res.* 14(6):1692-1700.

- 36 Garg K, Shih K, Barakat R, Zhou Q, Iasonos A and Soslow RA (2009). Endometrial carcinomas in women aged 40 years and younger: tumors associated with loss of DNA mismatch repair proteins comprise a distinct clinicopathologic subset. *Am J Surg Pathol* 33(12):1869-1877.
- 37 Eisen RN (2008). Quality management in immunohistochemistry. *Diagnostic Histopathology* 14(7):299-307.
- 38 Scurry J, Patel K and Wells M (1993). ACP Broadsheet 138. Gross examination of uterine specimens. *J Clin Pathol* 46:388-393.
- 39 Ali A, Black D and Soslow R (2007). Difficulties in Assessing the Depth of Myometrial Invasion in Endometrial Carcinoma *Int J. Gynecol Pathology* 26:155-123.
- 40 Fotiou S, Vlahos N, Kondi-Pafiti A, Zarganis P, Papakonstantinou K and Creatsas G (2009). Intraoperative gross assessment of myometrial invasion and cervical involvement in endometrial cancer: Role of tumor grade and size. *Gynecol. Oncol.* 112(3):517-520.
- 41 Yemelyanova A, Vang R, Seidman JD, Gravitt P and Ronnett B (2009). Endocervical adenocarcinoma with prominent endometrial or endomyometrial involvement simulating primary endometrial carcinoma. *Am J Surg Pathol.*
- 42 International Union against Cancer (UICC) (2002). *TNM Classification of Malignant Tumours*. Sobin L and Wittekind C. UICC, Geneva:184–187.
- 43 Benedetti-Panici P, Maneschi F, Cutillo G, D'Andrea G and Mancini N et al (1998). Anatomical and pathological study of retroperitoneal nodes in endometrial cancer. *Int J. Gynecol Cancer* 8:322-327.
- 44 Jarboe EA, Miron A, Carlson JW, Hirsch MS, Kindelberger D, Mutter GL, Crum CP and Nucci MR (2009). Coexisting intraepithelial serous carcinomas of the endometrium and fallopian tube: frequency and potential significance. *Int J. Gynecol Pathology* 28:308-315.
- 45 Snyder MJ, Bentley R and Robboy SF (2006). Transtubal spread of serous adenocarcinoma of the endometrium: an underrecognized mechanism of metastasis. *Int J. Gynecol Pathology* 25:155-160.
- 46 Mulvany NJ, Arnstein M and Ostor AG (1997). Fallopian tube cytology: a histocorrelative study of 150 washings. *Diagnostic Cytopathology* 16(6):483-488.
- 47 Lee Y, Miron A, Drapkin R, Nucci MR, Medeiros F, Saleemuddin A, Garber J, Birch C, Mou H, Gordon RW, Cramer DW, McKeon FD and Crum CP (2007). A

- candidate precursor to serous carcinoma that originates in the distal fallopian tube. *J Pathol.* 211(1):26-35.
- 48 Semmel DR, Folkins AK, Hirsch MS, Nucci MR and Crum CP (2009). Intercepting early pelvic serous carcinoma by routine pathological examination of the fimbria. *Mod. Pathol.* 22:985-988.
- 49 Clement PB and Young RH (2004). Non-endometrioid carcinomas of the uterine corpus: A review of their pathology with emphasis on recent advances and problematic aspects. *Advances in Anatomic Pathology* 11(3):117-142.
- 50 Thompson L, Chang B and Barsky SH (1996). Monoclonal origins of malignant mixed tumors (carcinosarcomas). *Am J Surg Pathol* 20(3):277-285.
- 51 Geisinger KR, Homesley HD, Morgan TM, Kute TE and Marshall RB (1986). Endometrial adenocarcinoma: a multiparameter clinicopathologic analysis including DNA profile and the sex steroid hormone receptors. *Cancer* 58:1518-1525.
- 52 Christopherson WM, Connelly PJ and Alberhasky RG (1983). Carcinoma of the endometrium: V. an analysis of prognosticators in patients with favourable subtypes and stage I disease. *Cancer* 51:1705-1710.
- 53 Zaino RJ, Kurman RJ, Herbold D, Gliedman J, Bundy BN and Voet R et al (1991). The significance of squamous differentiation in endometrial carcinoma. *Cancer* 68:2293-2302.
- 54 Eltabbakh GH, Shamonki J and Mount SL (2005). Surgical stage, final grade, and survival of women with endometrial carcinoma whose preoperative endometrial biopsy shows well-differentiated tumors. *Gynecol. Oncol.* 99(2):309-312.
- 55 Boronow RC, Morrow CP, Creasman WT, Disaia PJ, Silverberg SG, Miller A and Blessing JA (1984). Surgical staging in endometrial cancer: clinical-pathologic findings of a prospective study. *Obstet Gynecol* 63:825-832.
- 56 Creasman WT, Morrow CP, Bundy BN, Homesley HD, Graham JE and Heller PB (1987). Surgical pathologic spread patterns of endometrial cancer. *Cancer* 60:2035-2041.
- 57 Narayan K, Rejeki V, Herschtal A, Bernshaw D, Quinn M, Jobling T and Allen D (2009). Prognostic significance of several histological features in intermediate and high-risk endometrial cancer patients treated with curative intent using surgery and adjuvant radiotherapy. *Journal of Medical Imaging and Radiation Oncology* 53:107-113.

- 58 Williams JW and Hirschowitz L (2005). Assessment of uterine wall thickness and position of the vascular plexus in the deep myometrium: implications for the measurement of depth of myometrial invasion of endometrial carcinomas. *Int J. Gynecol Pathology* 25:59-64.
- 59 Longacre TA and Hendrickson MR (1999). Diffusely infiltrative endometrial adenocarcinoma: an adenoma malignum pattern of myoinvasion *Am J Surg Pathol* 23:69-78.
- 60 Marshall DS, Hummer A and Thaler HT et al (2003). Myometrial invasion patterns are associated with lymphovascular invasion in endometrioid adenocarcinomas of the endometrium. *Mod. Pathol.* 16:200A.
- 61 Murray SK, Young RH and Scully RE (2003). Unusual epithelial and stromal changes in myoinvasive endometrioid adenocarcinoma: a study of their frequency, associated diagnostic problems and prognostic significance. *Int J. Gynecol Pathology* 22:324-333.
- 62 Inoue Y, Obata K and Abe K et al (1996). The prognostic significance of vascular invasion by endometrial carcinoma. *Cancer* 78:1447-1451.
- 63 Gal D, Recio F and Zamurovic D et al (1991). Lymphovascular space involvement: a prognostic indicator in endometrial adenocarcinoma. *Gynecol. Oncol.* 42:142-145.
- 64 Jiang L, Malpica A, Deavers MT, Guo M, Villa LL, Nuovo G, Merino MJ and Silva EG (2010). Endometrial endometrioid adenocarcinoma of the uterine corpus involving the cervix: some cases probably represent independent primaries. *Int J. Gynecol Pathology* 29:146-156.
- 65 Tambouret R, Clement PB and Young RH (2003). Endometrial endometrioid adenocarcinoma with a deceptive pattern of spread to the uterine cervix: a manifestation of stage IIb endometrial carcinoma liable to be misinterpreted as an independent carcinoma or a benign lesion. *Am J Surg Pathol* 27(8):1080-1088.
- 66 Fadare O and Zheng W (2008). Endometrial Glandular Dysplasia (EmGD): morphologically and biologically distinctive putative precursor lesions of Type II endometrial cancers. *Diagn. Pathol* 3:6.
- 67 Yi X and Zheng W (2008). Endometrial glandular dysplasia and endometrial intraepithelial neoplasia. *Curr Opin Obstet Gynecol.* 20(1):20-25.
- 68 Zheng W, Liang SX, Xiaofang Y, Ulukus EC, Davis JR and Chambers SK (2006). Occurrence of endometrial glandular dysplasia precedes uterine papillary serous carcinoma. *Int J. Gynecol Pathology* 26:38-52.

- 69 McCluggage WG (2006). Immunohistochemical and functional biomarkers of value in female genital tract lesions. *Int J. Gynecol Pathology* 25:101-120.
- 70 Shutter J, Atkins KA, Ghartey K and Herzog TJ (2007). Clinical applications of immunohistochemistry in gynaecological malignancies. *Int J. Gynecol Cancer* 17:311-315.
- 71 Herrington CS (2009). Recent advances in molecular gynaecological pathology. *Histopathology* 55:243-249.
- 72 Valenstein PN (2008). Formatting pathology reports: applying four design principles to improve communication and patient safety. *Archives of Pathology and Laboratory Medicine* 132(1):84-94.
- 73 FIGO Committee on Gynecological Cancer (2009). Revised FIGO staging for carcinoma of the vulva, cervix and endometrium. *Int. J. Gynecol. Obstet.* 105:103-104.