

Structured Pathology Reporting of Cancer Newsletter

December 2011. Issue 8.

Index :

(Click on a title below to go directly to that story)

- [New protocols](#)
- [Haven't visited the website yet?](#)
- [International collaboration](#)
- [Structured pathology in the news!](#)
- [Wanted: colorectal cancer reports](#)
- [Brain teaser](#)

PDF versions of this newsletter are available from the structured pathology website.

Welcome to the last edition of the Structured Pathology Reporting of Cancer newsletter for 2011.

This newsletter is intended to provide information on the project to expand and promote the use of structured pathology reporting of cancer.



Season's Greetings

Wishing you all the very best for this holiday season and a very HAPPY NEW YEAR!

New protocols!

The RCPA Council has recently endorsed the following structured pathology reporting protocols:

- Testicular tumours
- Oral cancer

Visit the RCPA website and download a protocol or perhaps a hyperlinked guide. See more information on this below. Remember the guides are the easiest way to access the information in the protocols!

Keep an eye out for the Bladder cancer and Prostate cancer (Core Biopsy) protocols that will be available for open consultation in the new year!

Other protocols that are under way or in the planning stage are:

- Oesophageal and Gastro-oesophageal Junction cancer (both the Endoscopic resection (ER) and the Oesophagectomy and oesophago-gastrectomy specimens will be published as two separate protocols)
- Vulvar cancer
- Cervical cancer
- Adrenal gland tumours
- Gastrointestinal Stromal Tumours (GIST)
- Neuroblastoma (Paediatrics)
- Squamous cell carcinoma of the conjunctiva

Haven't visited the website yet?

If you haven't visited the RCPA website yet – there is a wealth of information available, just click on the link below:

www.rcpa.edu.au/Publications/StructuredReporting/cancerprotocols.htm

You get access to 14 structured pathology reporting protocols. These are grouped into categories such as gastrointestinal, and genitourinary etc for ease of access.

The following protocols are based on the 2010 AJCC/ICC 7th edition Cancer Staging Manual.

The guides, forms and request information sheets are provided for educational purposes and to support the implementation of structured pathology reporting of cancer.

- Guides are designed to be an "aide de memoire" when reporting and contain a condensed version of the standards and guidelines from the protocol. "Help" in the form of the relevant sections from the protocol is available by clicking on the hyperlinked standard or guideline number. The guides are the easiest way of accessing the wealth of information in the protocol. (You will need an active internet connection to view the information.)
- Forms are designed to provide a paper version of the checklist in Chapter 6 of the protocol, with response values and spaces for notes.
- Request information sheets are designed to provide guidance for clinicians requesting surgical pathology for specific cancers describing the type of information required by the pathologist to adequately assess the specimen.

Cancer Protocol	Guide	Form	Request Information
Gastrointestinal			
Colorectal V1.2, updated July 2010 (PDF, 362KB)	Guide (PDF) V1.2, 551KB	Form (PDF) V1.1, 559KB	Request (PDF) V1.0, 124KB
Gastric Cancer V1.0, Feb 2011 (PDF, 549KB)	Guide (PDF) V1.0, 154KB	Form (PDF) V1.0, 159KB	Request (PDF) V1.0, 129KB
Haematopoietic & Lymphoid Tumours			
Haematopoietic & Lymphoid Tumours V1.3, updated July 2010 (PDF, 190KB)	Guide (PDF) V1.0, 439KB	Form (PDF) V1.0, 456KB	Request (PDF) V1.0, 129KB
Lung			
Lung V1.3, updated July 2010 (PDF, 337KB)	Guide (PDF) V1.0, 439KB	Form (PDF) V1.2, 465KB	Request (PDF) V1.0, 119KB
Primary Cutaneous Melanoma			
Primary Cutaneous Melanoma V1.1, updated April 2010 (PDF, 242KB)	Guide (PDF) V1.1, 432KB	Form (PDF) V1.1, 456KB	Request (PDF) V1.0, 393KB
Prostate (Radical Prostatectomy)			
Prostate (Radical Prostatectomy) V1.1, updated April 2010 (PDF, 311KB)	Guide (PDF) V1.0, 469KB	Form (PDF) V1.0, 466KB	Request (PDF) V1.0, 87KB
Renal Parenchymal Malignancy (Renal Cell Carcinoma)			
Renal Parenchymal Malignancy (Renal Cell Carcinoma) V1.1, updated Nov 2011 (PDF, 247KB)	Guide (PDF) V1.0, 162KB	Form (PDF) V1.0, 170KB	Request (PDF) V1.0, 129KB
Testicular tumours			
Testicular tumours V1.0 Nov 2011 (PDF, 313KB)	Guide (PDF) V1.0, 327KB	Form (PDF) V1.0, 339KB	Request (PDF) V1.0, 146KB
Breast			
Breast V1.1, updated April 2010 (PDF, 148KB)	In development	To be developed	
Endometrium			
Endometrium V1.0, Feb 2011 (PDF, 417KB)	Guide (PDF) V1.0, 179KB	Form (PDF) V1.0, 187KB	Request (PDF) V1.0, 119KB
Soft Tissue Tumour Resection			
Soft Tissue Tumour Resection V1.0, Feb 2011 (PDF, 266KB)	Guide (PDF) V1.0, 179KB	Form (PDF) V1.0, 183KB	Request (PDF) V1.0, 129KB
Thyroid Cancer			
Thyroid Cancer V1.0 Feb 2011 (PDF, 927KB)	Guide (PDF) V1.0, 172KB	Form (PDF) V1.0, 179KB	Request (PDF) V1.0, 139KB
Oral Cancer			
Oral Cancer V1.0 Nov 2011 (PDF, 511KB)	Guide (PDF) V1.0, 219KB	Form (PDF) V1.0, 219KB	Request (PDF) V1.0, 524KB
Central Nervous System Tumours			
Central Nervous System Tumours V1.0, Feb 2011 (PDF, 126KB)	Guide (PDF) V1.0, 189KB	Form (PDF) V1.0, 147KB	Request (PDF) V1.0, 129KB

Click on the name of the protocol to open, you can review it online or save it locally.

Too busy to read the protocols?

Need quick information on what to report on a cancer??

Then just click on **'Guide'** next to the protocol you are interested in to open a guide like this Prostate guide (for Radical Prostatectomy) below:

A guide to Prostate Cancer (Radical Prostatectomy) Histopathology Reporting

Clinical details		Microscopic findings (cont.)	
S3.02 Pathology accession number	Text	S3.02 Extraprostatic extension (EPEx)	Negative Focal Extensive
S3.03 Principal clinician	Text		
S3.03 Surgical procedure	Text		
Nature of specimen			
S3.03 Clinical history (including Gleason grade and score of previous specimens)	Text		
S3.04 Previous therapy	Text		
S3.05 PSA (preoperative) value	Text		
S3.05 Relevant clinical information for intraoperative staging	Text		
S3.07 Comments	Text		
Macroscopic findings		Length of margin involvement	
S3.02 Weight of prostate gland without seminal vesicles	---	Length of margin involvement	--- mm
S3.03 Size of prostate gland			
Apex-base	--- mm		
Right-left	--- mm		
Anterior-posterior	--- mm		
S3.04 Seminal vesicles	Absent Present		
If present, what is size (in greatest dimension)			
S3.05 Lymph nodes	Absent Present		
If present:			
Site	Text		
Number	Text		
S3.07 Microscopic comments	Text		
Microscopic findings		Synthesis and overview	
S3.01 Tumour type	Text Subcapsular Type	S3.01 Tumour stage (AJCC/UICC)	See p2
S3.01 Diagnostic summary			
S3.01 Tumour location (target node(s))	A, anterior B, posterior L, left R, right Other (spec)		
Tumour location (other nodes > 10 mm)			
S3.02 Tumour volume estimate	--- cm ³		
Qualitative description			
S3.02 Gleason score (see p2)	Text		
Primary	---		
Secondary	---		
Tertiary	---		

NOTES

S3.02 Gleason score

Gleason grade

- Observe glands (small regular glands forming a circumferential rim) and note any atypical prostatic glands (irregular, crowded, cribriform, fused, or fused glands) that may have irregular outlines or margins. Do not use for needle biopsy specimens.
- Glands more than 4 mm apart, not close together, may be considered but they have irregular outlines or margins. Do not use for needle biopsies and T4b biopsies. Do not use for needle biopsies.
- Observe glandular architecture with marked variation in size and shape, infiltration in and amongst benign prostatic tissue (see grade 4 below).
- Fused micro acinar glands, or diffuse glands with poorly formed lumens, large cribriform/irregular glands, hyperchromatic.

Report if any glandular differentiation - solid sheets, cords or single cells. Comment on:

Number of glands present	Proportion of glands present	Comments
1	One of 2, 3, 4 or 5 only	Double grade to get lower (eg 4+4=8)
2	Primary and secondary	Report both grades, dominant pattern* first (2+3, 3+4, 4+3, ...)
3	Secondary grade is lower and of limited amount	Ignore lower grade - 4+3 becomes 4+4 Report for dominant grade +/- non-dominant (smaller) grade if of higher grade (if present)
4	Secondary grade is higher and of limited amount	Ignore higher grade - 3+3 becomes 3+4 Report for dominant grade +/- non-dominant (smaller) grade if of higher grade (if present)

Notes:

- Dominant (primary) grade is that which occupies the greatest area.
- For radical prostatectomy specimens secondary grade is defined as that which occupies the second greatest area.
- For radical prostatectomy specimens tertiary grade is defined as that which occupies the third greatest area (provided that it is higher than the primary and secondary grades).

Gleason scoring of unusual patterns

Pattern	Morphology	Comment
Vacuoles	Cytoplasmic vacuolation	Grade as if vacuoles were glands, use the underlying architecture
Small well-developed	Columnar, fibromuscular	Grade as if were absent
Comminuted structures		Grade as 4
Primary gland change		Grade as if were absent
Microinvasion		Do not assign a grade

Gleason scoring of cribriform patterns

Grade 3 Small, well circumscribed, round with smooth outline, regular size. Should be used only if regular.

Grade 4 Irregular cribriform and fused gland masses (smaller) include nests of cribriform patterns

Grade 5 Any cribriform area with necrosis

Comments:

- Do not include in score
- Infiltrative
- Irregular architecture of high grade
- Structure of Grade 4 or 5 (if present)
- IR = primary intraprostatic neoplasia

S5.01 Tumour stage (AJCC/UICC)**

Pathologic primary tumor (T)

- T1X Primary tumor cannot be assessed
- T1 No evidence of primary tumor
- T1X Organ Confined
- T1X Unilateral, one half of one side or less
- T1X Unilateral, involving more than one half side but not both sides
- T1X Bilateral disease
- T1X Pathologic extension
- T1X Pathologic extension or microscopic invasion of bladder neck**
- T1X Seminal vesicle invasion
- T1X Invasion of ureter, bladder muscle and/or pelvic wall.

Notes:

- Divide into the prostate apex or site (but not beyond) the prostate capsule or not classified as T1, but as T1.
- Note: There is no pathologic T1 classification
- Note: Positive regional margin should be indicated by an R1 descriptor (see below Microscopic disease)

Pathologic regional lymph nodes (N)

- N0 Regional lymph nodes not sampled.
- N1 No positive regional nodes.
- N1X Metastasis in regional node(s).

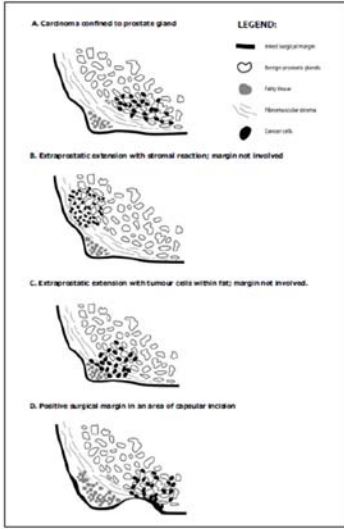
Clinical and pathologic distant metastasis (M)

- M0 No distant metastasis
- M1 Distant metastasis
- M1X Non-regional lymph node(s)*
- M1X Bone(s)
- M1X Other site(s) with or without bone disease
- *Note: When more than one site of metastasis is present, the most advanced category is used. (M1X is most advanced)

**** Used with the permission of the American Joint Committee on Cancer (AJCC), Chicago, Illinois. The original source for this material is the AJCC Cancer Staging Manual, Seventh Edition (2002) published by Springer International Publishing AG. www.springer.com**

GUIDES are the easiest way to get a list of the reporting requirements and responses and they are also the best way to get access to the commentary from the protocol. Simply click on the hyperlinked standard or guideline number and the information pops up.

Below is the information which pops up when you click on the number S3.03 in the guide.

<p>CS3.03 Extraprostatic extension (EPE) must be recorded. (see Figure S3.03)</p> <p>CS3.03a Extraprostatic extension (EPE) refers to the presence of neoplastic glands outside the prostate in the periprostatic tissue. This became accepted terminology at a 1996 Consensus Conference,¹⁷ and replaces terms such as extracapsular or extraglandular invasion, penetration, and perforation.</p> <p>CS3.03b Specify whether the EPE is negative, focal or extensive (see definitions in CS3.03f).</p> <p>CS3.03c Specify the location of the EPE (ie quadrant and base/mid/apex).</p> <p>CS3.03d The assessment of EPE can be difficult, as the prostate is not surrounded by a discrete, well defined fibrous capsule. Adding to the difficulty, Chuang and Epstein¹⁸ note that there is often a fibrotic reaction in the vicinity of EPE, and the neoplastic extraprostatic glands are often seen in fibrous tissue, not fat. Therefore, EPE can be identified in several different situations and can be diagnosed by one of the following:</p> <ul style="list-style-type: none"> • The presence of neoplastic glands abutting or within periprostatic fat (most useful at the lateral, posterolateral and posterior aspects of the gland). • Neoplastic glands surrounding nerves in the neurovascular bundle (posterolaterally). • The presence of a nodular extension of tumour beyond the periphery of the prostate. This latter situation is best identified at low power magnification. In this assessment, the edge of the prostate is defined as the plane between fat and the condensed fibromuscular prostatic stroma which is best initially determined in a region without distortion by tumour. Tracking along the edge of the prostate at low power, EPE is present when there is bulging of the tumour beyond the normal rounded contour of the prostate gland. <p>CS3.03e A 'capsule' cannot be readily identified at the base or apex, and in these sites it is more important to comment on the margins and adequacy of excision. It can be particularly challenging for pathologists to identify the boundary of the prostate gland at the apex. At this site, benign glands are frequently admixed with skeletal muscle and the presence of neoplastic glands in skeletal muscle does not necessarily constitute EPE at the apex. The majority of survey respondents at the 2009 ISUP Consensus Conference in Boston believe there is no reliable method to diagnose EPE in sections from the prostatic apex.¹⁹</p> <p>Similarly, the assessment of EPE at the anterior aspect of the prostate may be difficult as the prostatic stroma blends in with extraprostatic fibromuscular tissue, but in this region EPE can be diagnosed when the carcinoma appears to extend beyond the margin of the normal prostatic glandular tissue (see the 3rd bullet point in CS3.03d).</p> <p>CS3.03f The degree of extraprostatic extension can be further classified as focal or extensive (also referred to as 'established' or 'nonfocal'). Focal is defined as extraprostatic glands which occupy no more than one high power field on no more than two sections.²⁰ Extensive EPE represents anything more than this.</p>	<p>CS3.03g The identification of any extraprostatic extension is important, as both focal and extensive EPE are associated with a significantly higher risk of recurrence at both 4 and 10 years.²¹ In one study of prediction of progression following radical prostatectomy,²² the risk of disease progression in node negative patients with negative seminal vesicles at 10 years for organ confined disease was 16%, focal EPE 33% and extensive EPE 42% (all values significant $P = 0.001$).</p> 
---	---

“Add to favourites” and it’s always at your finger tips.

International collaboration

As a result of the success of the pilot project to deliver internationally agreed datasets for Melanoma, Lung, Endometrium and Prostate (Radical Prostatectomy) the International Collaboration on Cancer Reporting (ICCR) committee agreed to seek funding and a governance model to support future efforts.

Seeking an appropriate governance structure, one that is truly international and which can provide both the support and influence to assist the project, was deemed the highest priority. Since then, there has been a flurry of activity identifying organisations and speaking to individuals who can further this effort which has lead to some very promising opportunities which hopefully will bear fruit in the next few months.

To further this opportunity and to continue the momentum to date the ICCR are proposing a second pilot consisting of the development of a cancer dataset with an expanded collaborative group beyond the initial four countries. The ICCR would also like to ensure acceptance of the existing four developed protocols by undertaking an international consultation to ratify the outcomes.

The work on the international cancer datasets has highlighted a number of common themes and issues including development of standard information models and the binding of terminologies such as LOINC or SNOMED CT to ensure accuracy of information and ease of

messaging between systems. This ties in well with the Pathology Units and Terminology Standardisation (PUTS) Project which is currently underway at the college.

Also of interest is the common implementation issues the ICCR countries face. The links developed through this international work might offer some opportunities in this area in the coming months.

Structured pathology in the news!

Several articles have been published in *Pathology*, the official journal of the RCPA, which are of interest to structured pathology reporting of cancer. Members can log on to the RCPA website and access the Pathology journal to review articles of interest such as:

1. Populating structured reports automatically
(This article is relevant to our story "Wanted: colorectal cancer reports" below)
2. Prognostic factors in prostate cancer. Key elements in structured histopathology reporting of radical prostatectomy specimens.
3. Surgical pathology reporting at the crossroads: beyond synoptic reporting.
4. Synoptic reporting improves histopathological assessment of pancreatic resection specimens.
5. Optimising the management of soft tissue tumours

Wanted: colorectal cancer reports

We are seeking to accumulate a reasonable bundle of colorectal cancer reports to enable an audit on the use of Structured Pathology Reporting.

Professor Jon Patrick of the University of Sydney will be undertaking an audit using his Natural Language Processing (NLP) methodology to evaluate both the use of and the completeness of colorectal cancer reports as compared to the published protocols.

At this stage the reports submitted will be used to:

- a) define the methodology for assessing reports and gain insight into the accuracy of the results, and
- b) to establish an Australasian baseline against which we can assess progress in the future.

We are not measuring performance or use at an individual laboratory level.

It would be most helpful if you could send in a de-identified colorectal cancer report to include in the audit. Send your reports to Meagan Judge at MeaganJ@RCPA.EDU.AU.

Brain teaser

Here's something to relax with over the holidays.....

In a street there are 5 houses, painted 5 different colours. In each lives a person of a different nationality. The five home owners each drink a different beverage, smokes a different brand of cigar and keeps a different pet.

The question..... *who keeps the fish?*

HINTS:

1. The Brit lives in the red house
2. The Swede has a dog
3. The Dane drinks tea
4. The green house is on the left of the white house
5. The owner of the green house drinks coffee
6. The person who smokes Pall Mall has birds
7. The owner of the yellow house smokes Dunhills
8. The man living in the centre house drinks milk
9. The Norwegian lives in the first house
10. The man who smokes Blends lives next to the one who has cats
11. The man who has horses lives next to the man who smokes Dunhills
12. The man who smokes Blue Master drinks beer
13. The German smokes Prince
14. The Norwegian lives next to the blue house
15. The man who smokes Blends has a neighbor who drinks water

It is said that Albert Einstein wrote this riddle in the early 20th century and stated that 98% of the population would not be able to solve it. (To find out the answer email Meagan at MeaganJ@RCPA.EDU.AU or search google!).

Structured Pathology Reporting Project Manager:

Meagan Judge

The Royal College of Pathologists of Australasia

Phone: +61 2 8356 5854

Mobile: 0402 891031

Fax: +61 2 8356 5808

Address: 207 Albion Street, Surry Hills, NSW 2010, Australia

WEBSITE: www.rcpa.edu.au/Publications/StructuredReporting.htm

You have received this message because you are listed
as a stakeholder of the national structured pathology reporting project.

If you do not want to receive this newsletter in the future, please email: MeaganJ@RCPA.EDU.AU